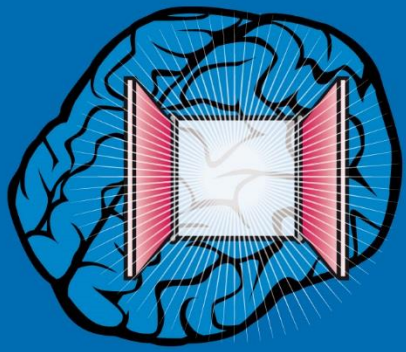

Publieksdag Hersentumoren

Zaterdag 16 maart 2019
De Landgoederij, Bunnik

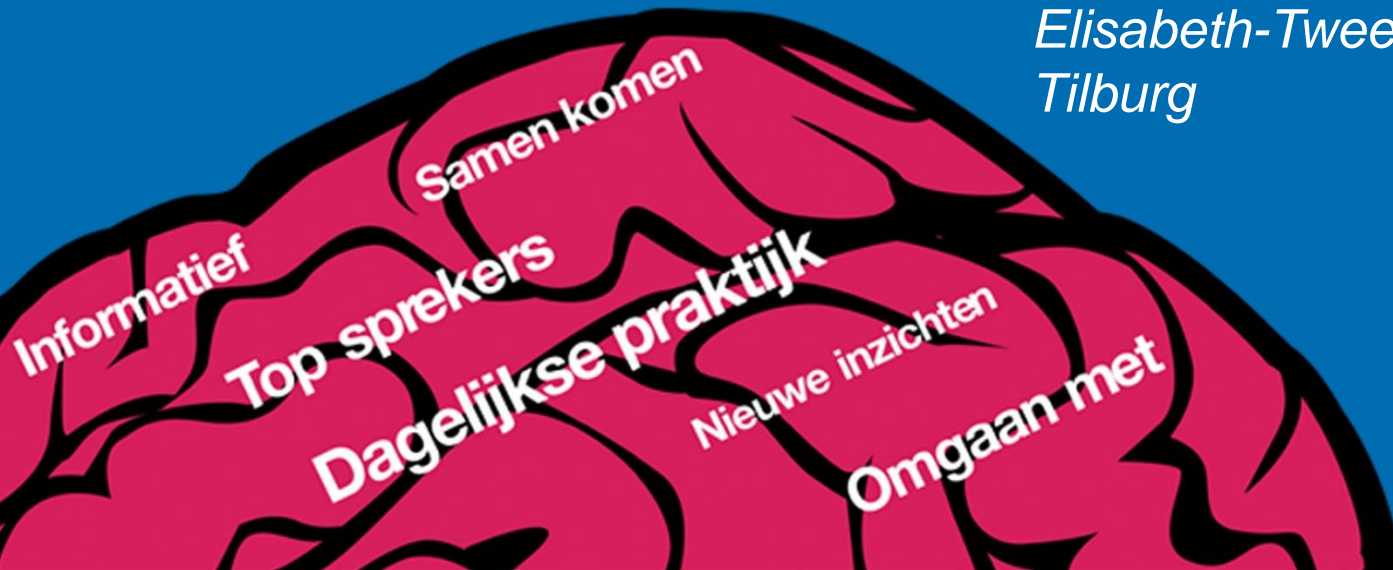Operatie technieken voor hersentumoren

Geert-Jan Rutten

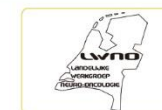Neurochirurg

Elisabeth-Tweesteden Ziekenhuis

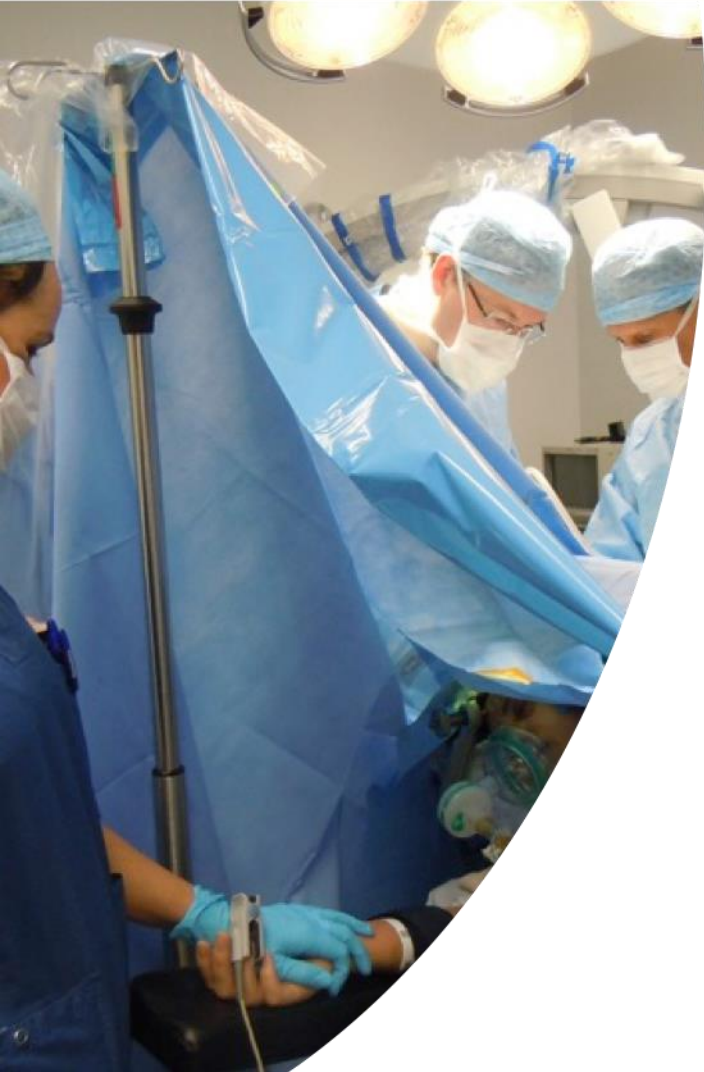Tilburg



In samenwerking met:



Technische hulpmiddelen



vóór operatie

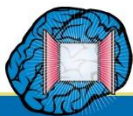
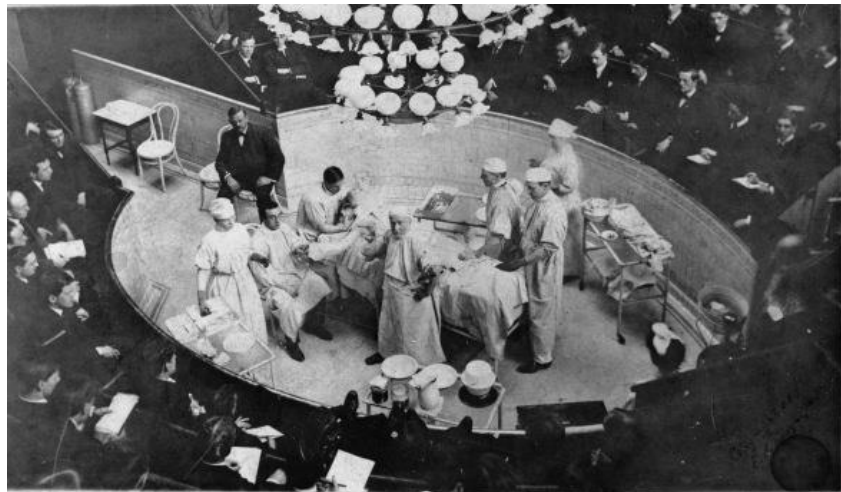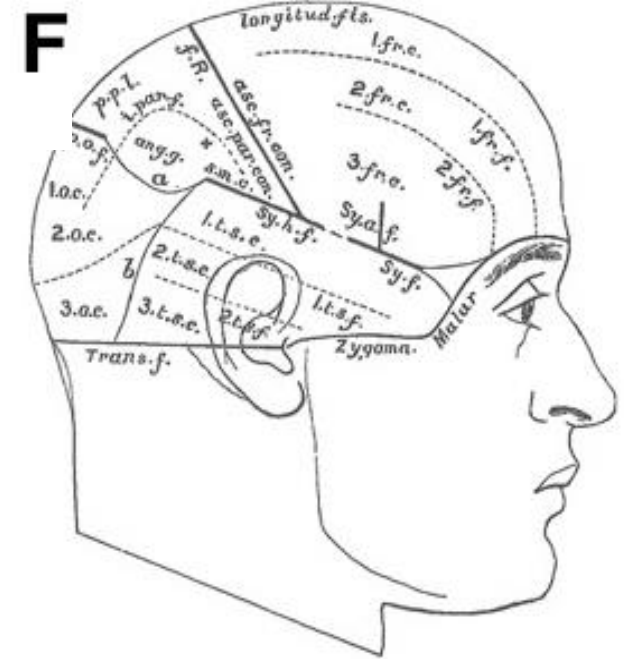
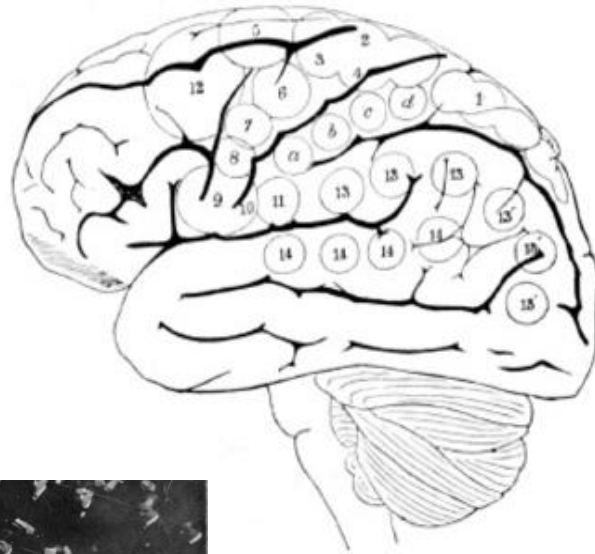
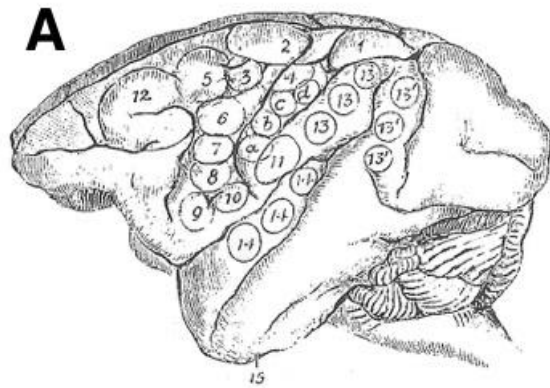
- Beeldvorming om anatomie in beeld te brengen
- Beeldvorming om functie in beeld te brengen

tijdens operatie

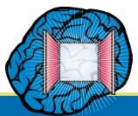
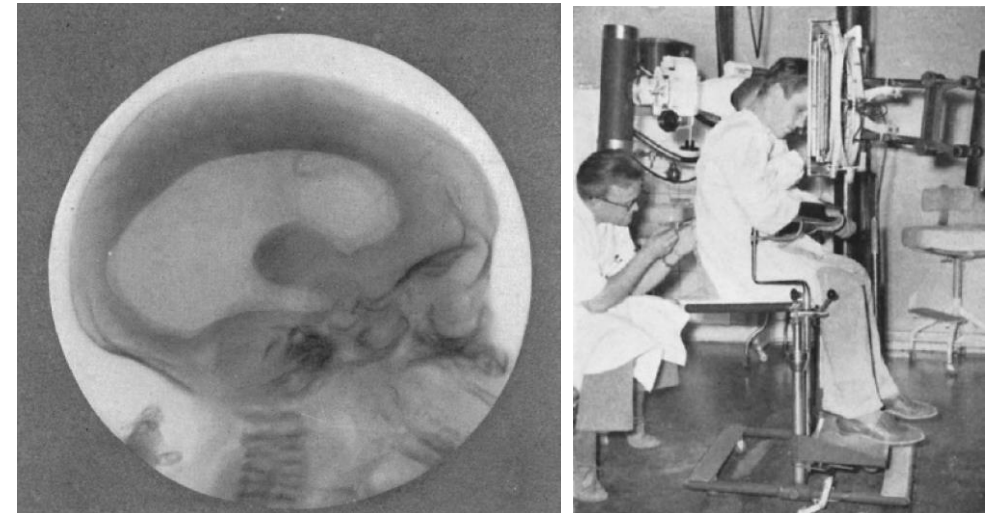

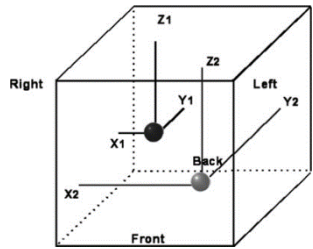
- Microscoop
- Neuronavigatie, echo, MRI
- Fluorescentie
- Elektrische hersenstimulatie (wakkere operatie)



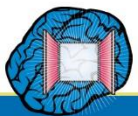
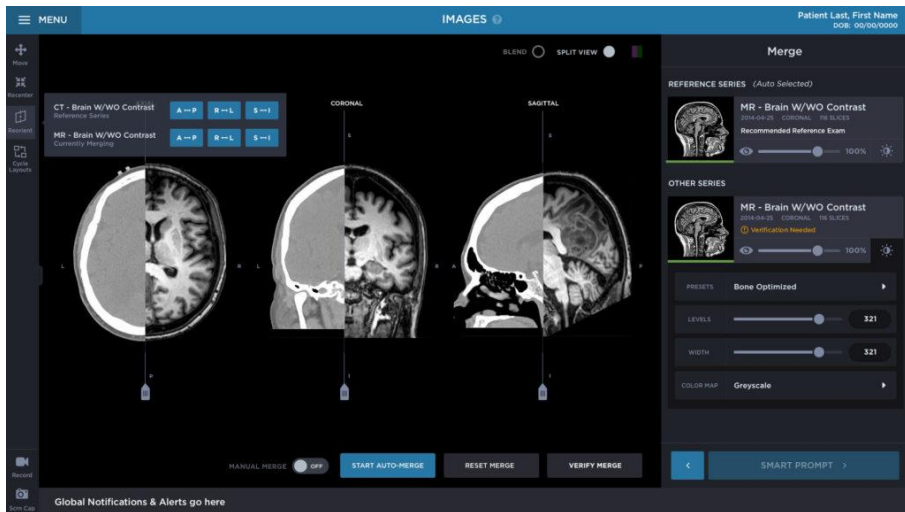
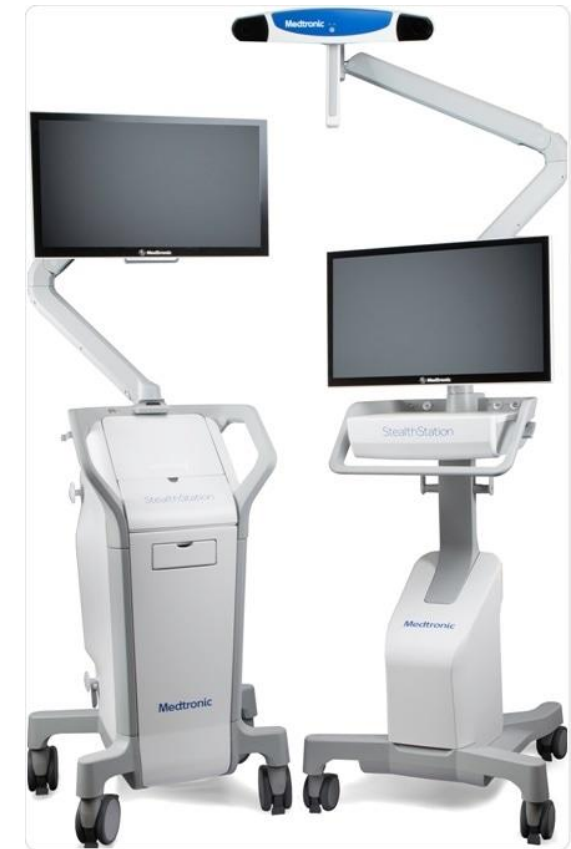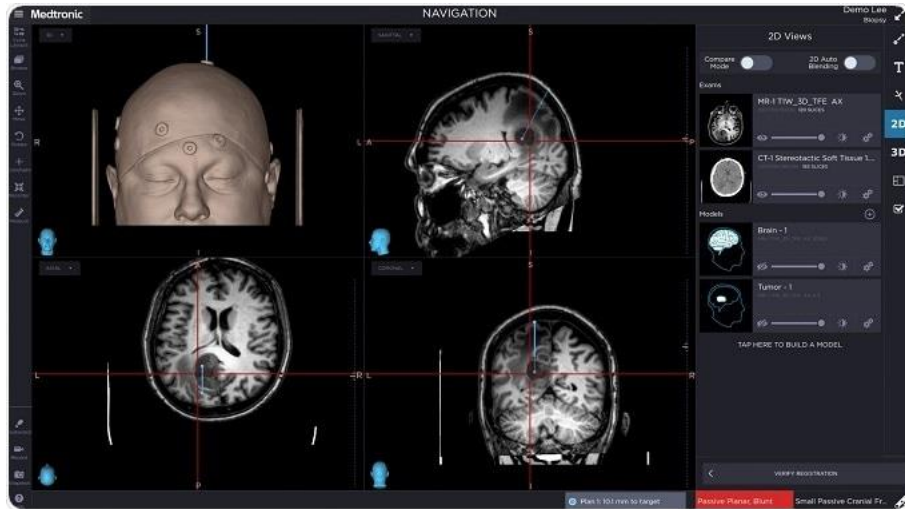
De eerste operatie van een hersentumor (1894)



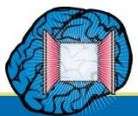
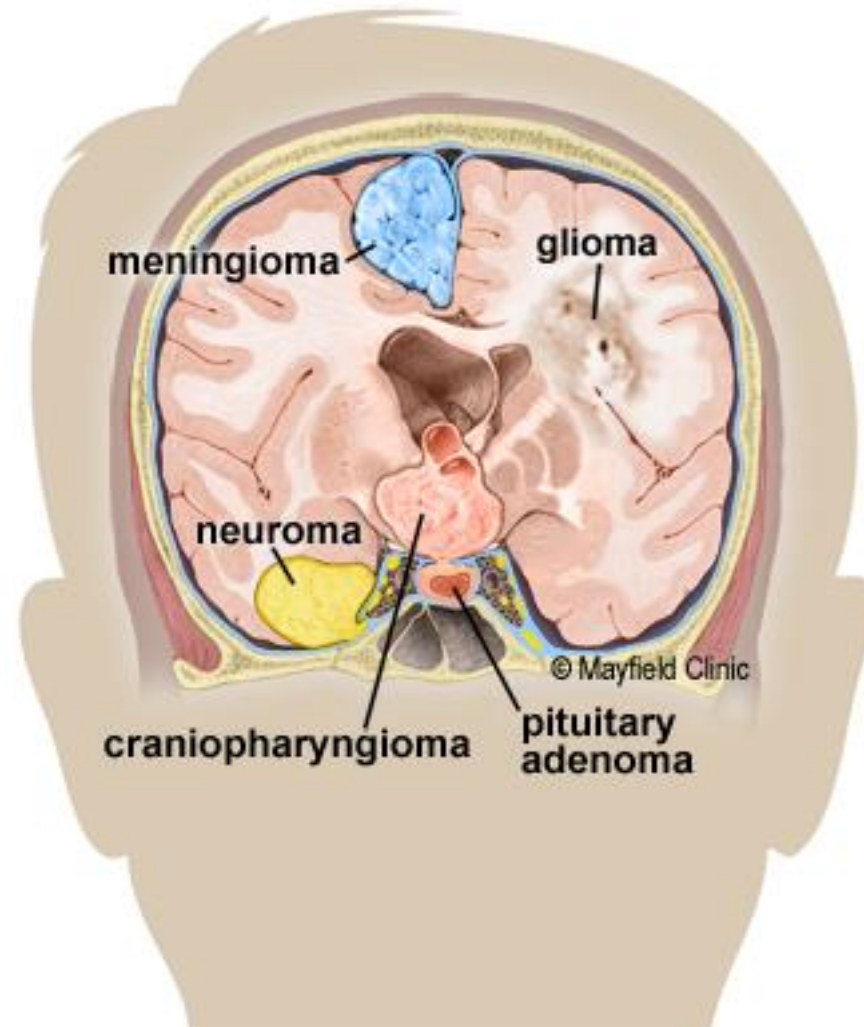
Lokalisatie



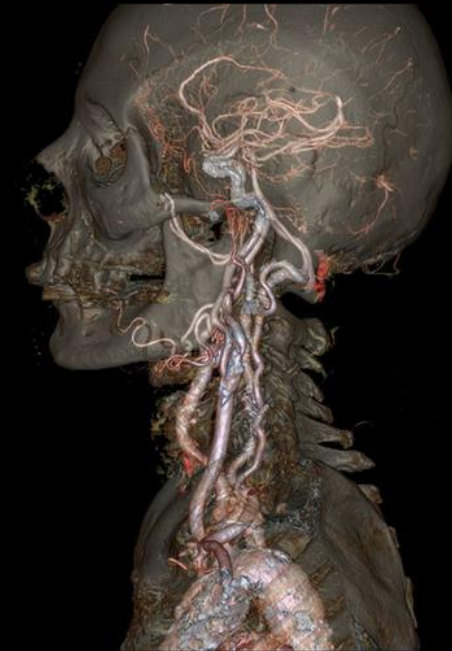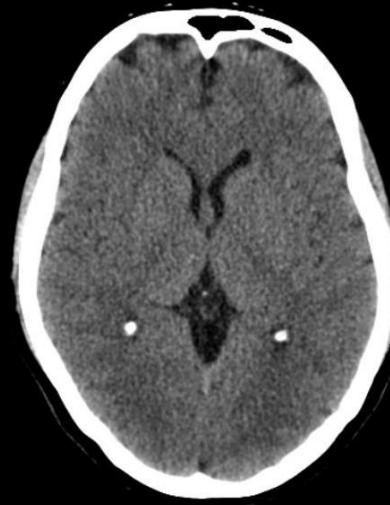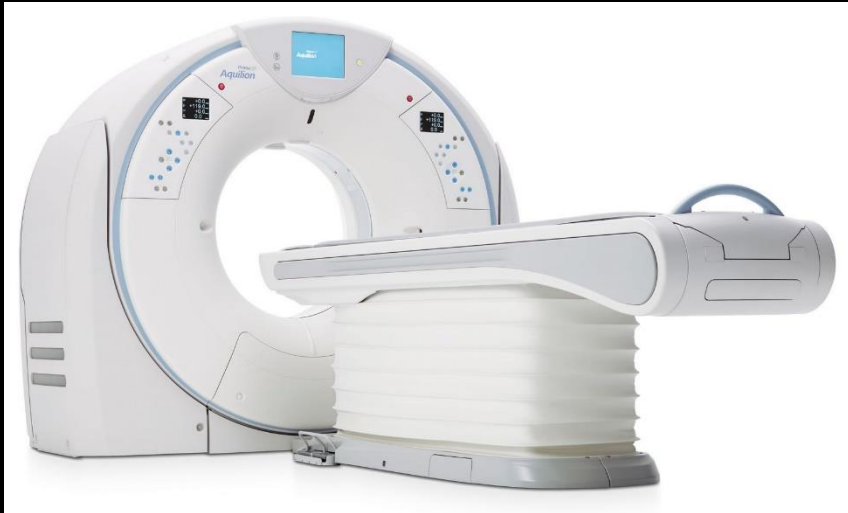Neuronavigatie



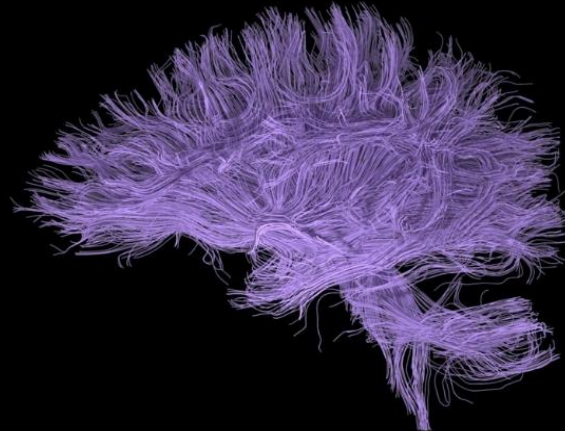
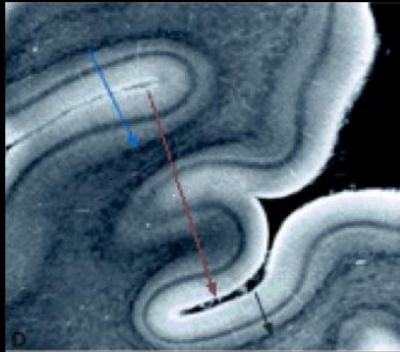
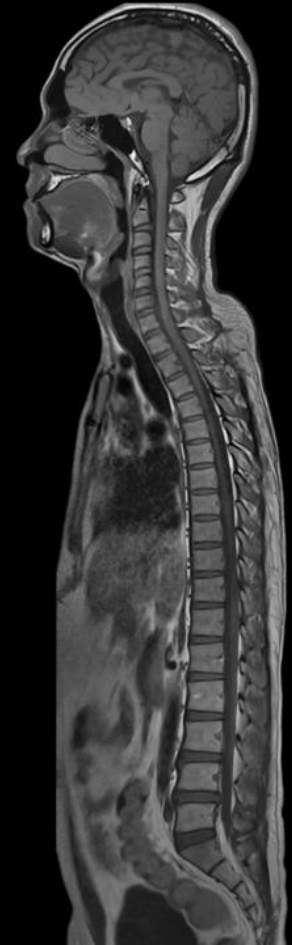
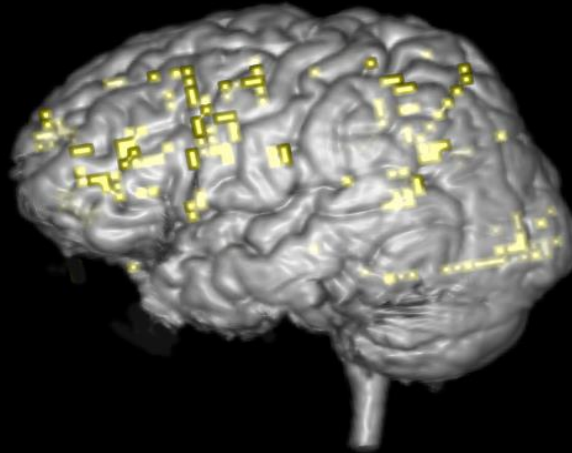
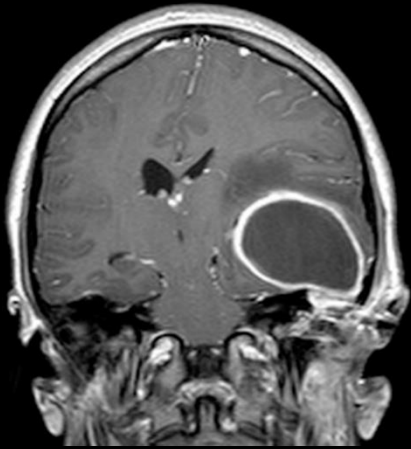
Hersentumoren: veel onderlinge verschillen



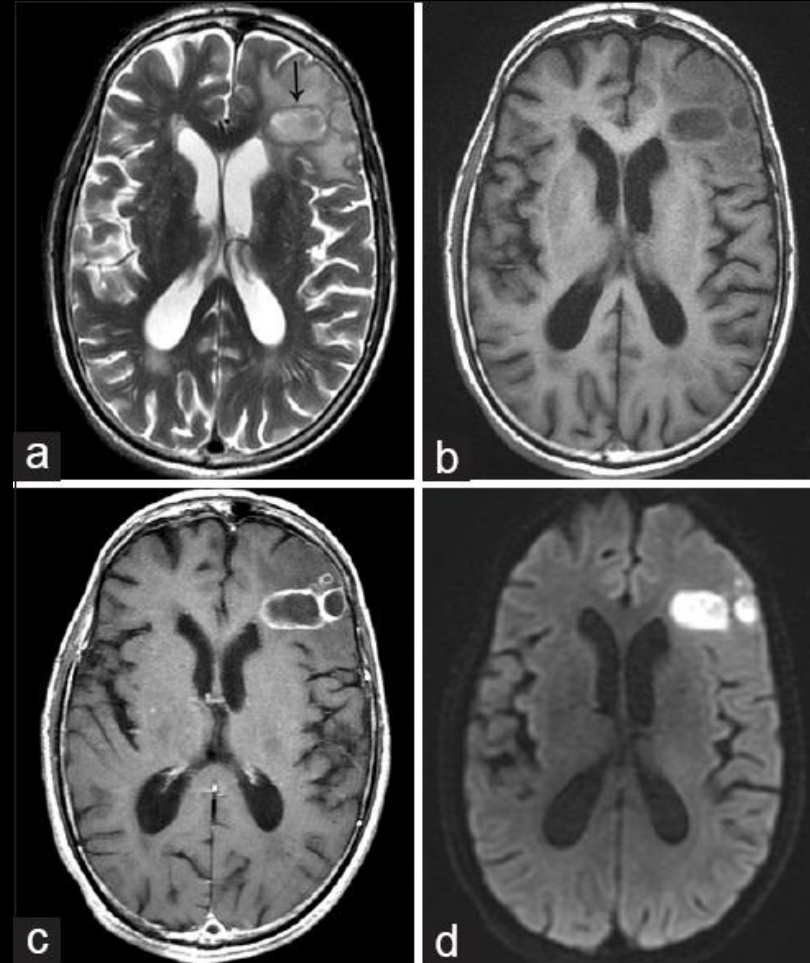
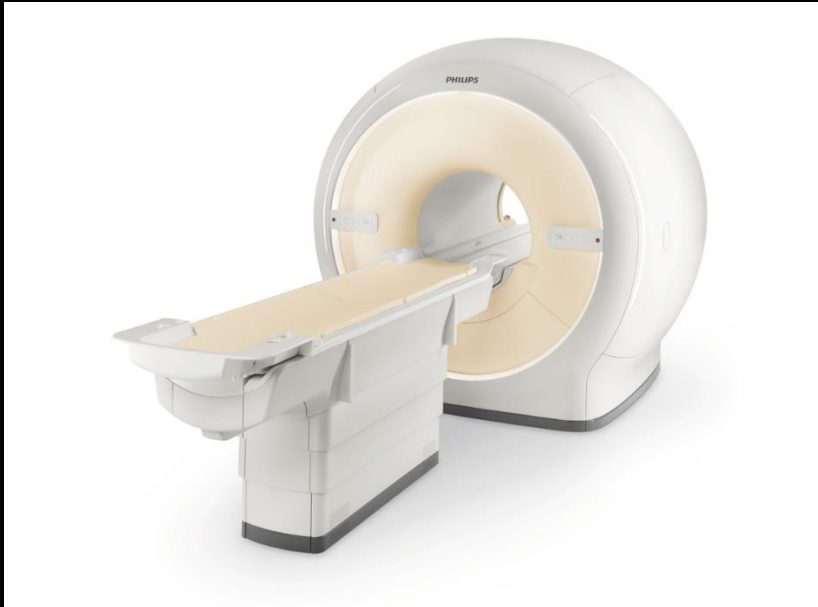Preoperatief-- CT



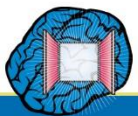
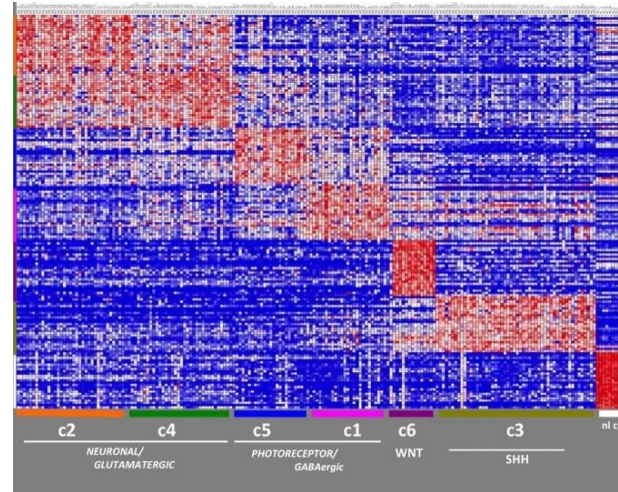
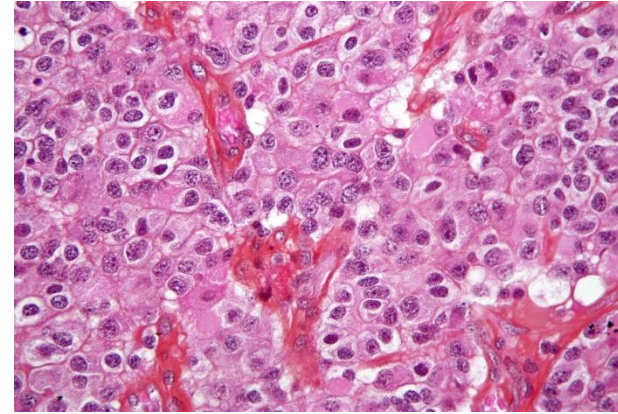
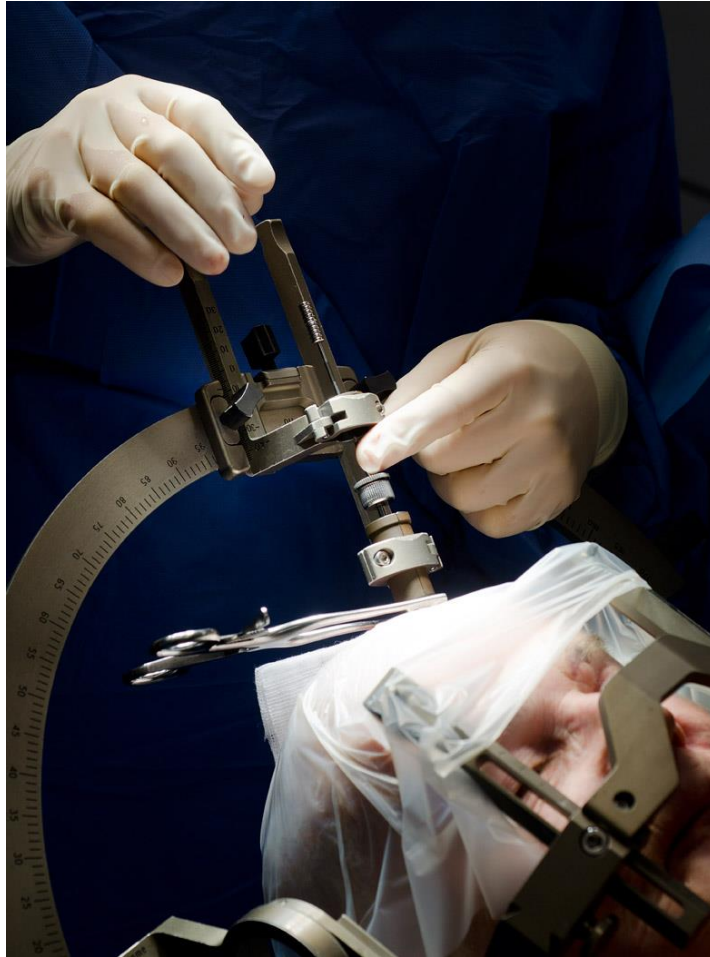
Preoperatief-- MRI



MRI -- diagnostiek



Vuistregel: weefsel nodig voor stellen diagnose

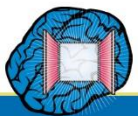


Verschillende perspectieven

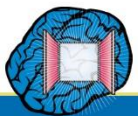
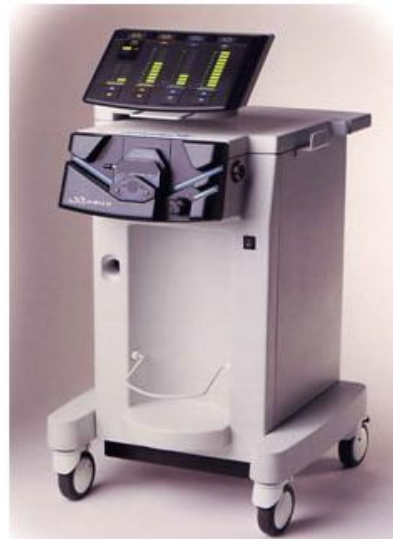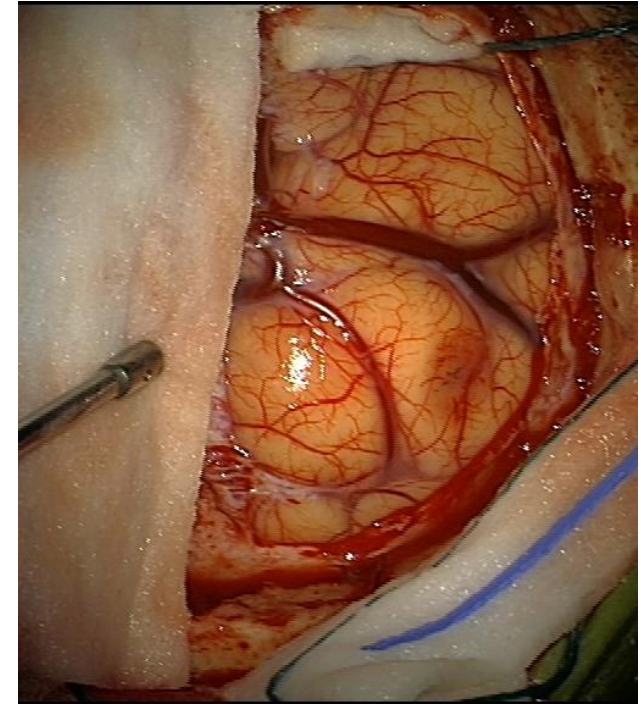
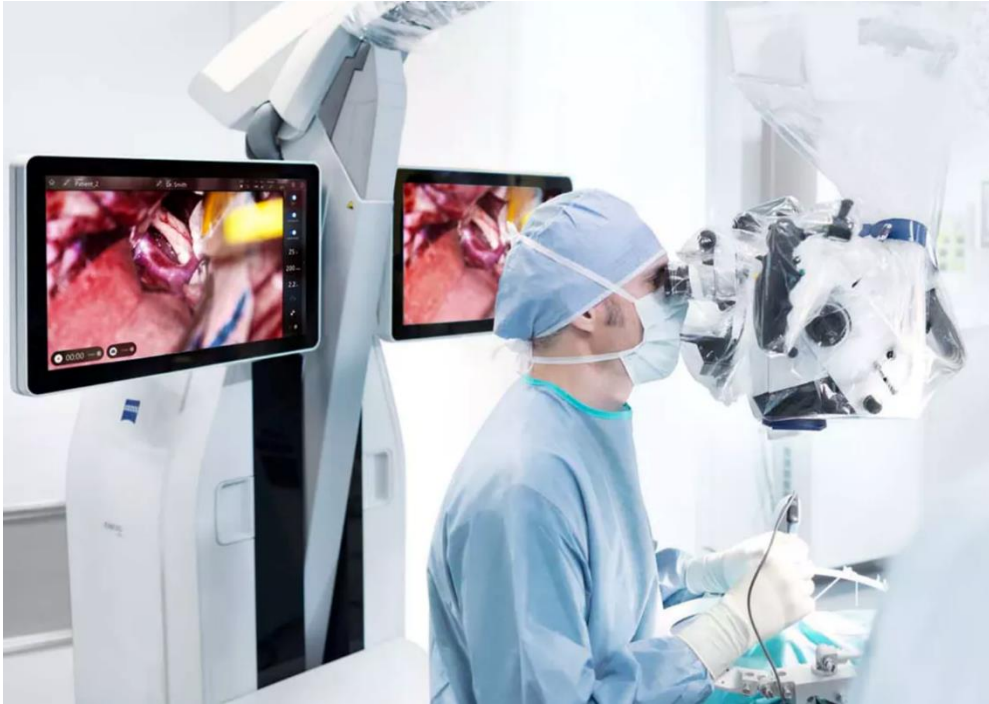Operatie
Karnovsky PS
Medicatie
Chemotherapie
Radiotherapie
Overleving
Recidief kans



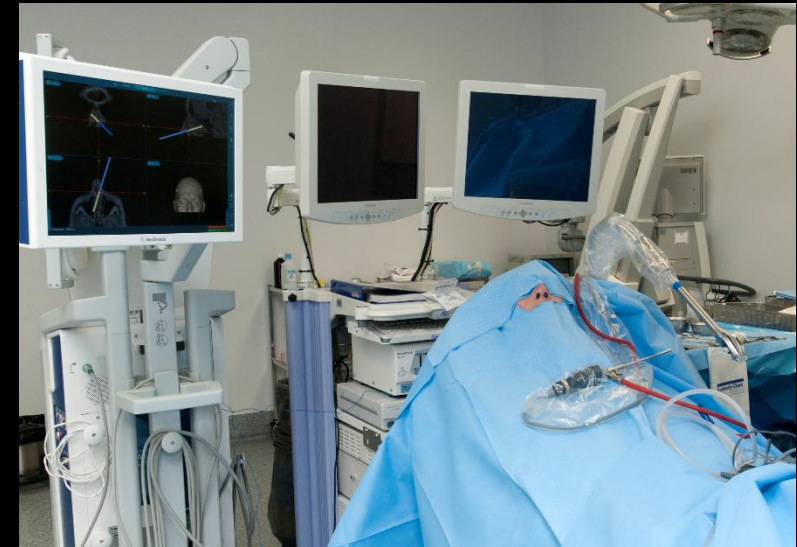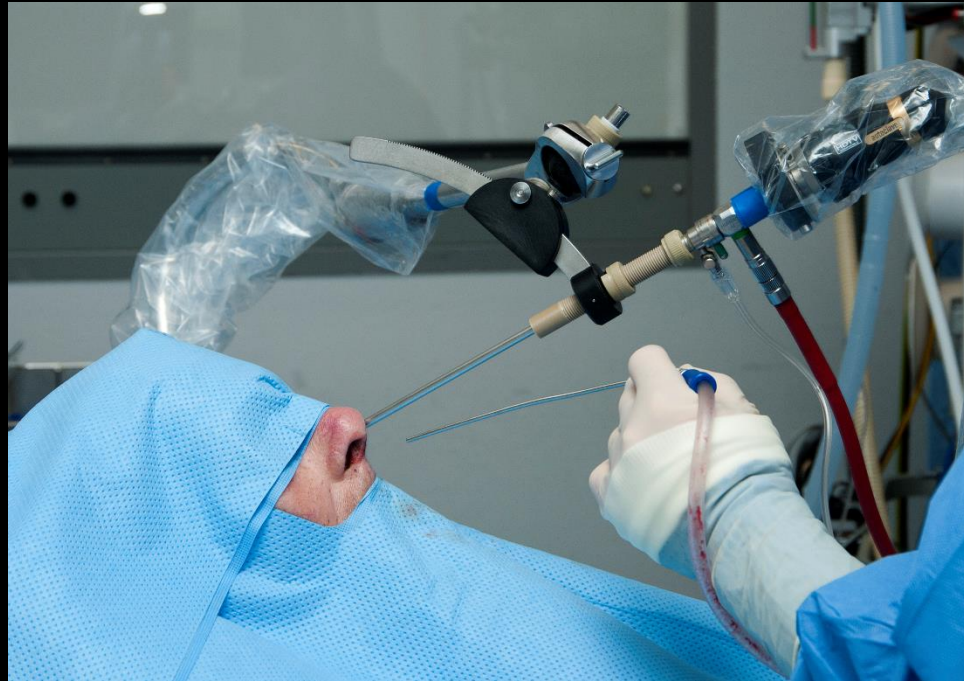
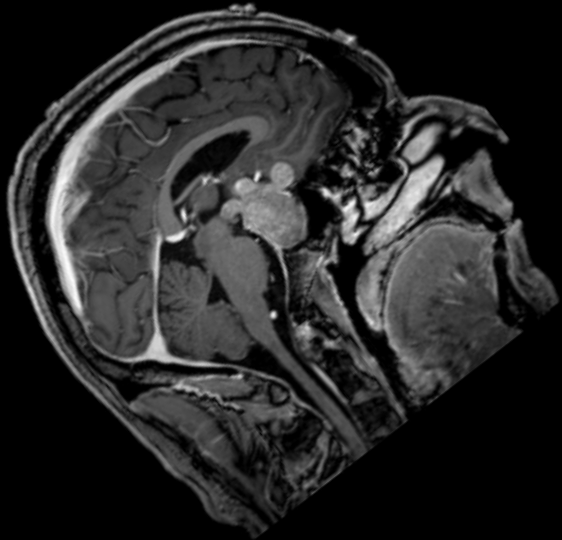
Complicaties/risico's
Moeheid
Concentratie problemen
Gedragsveranderingen
Gezin
Werk



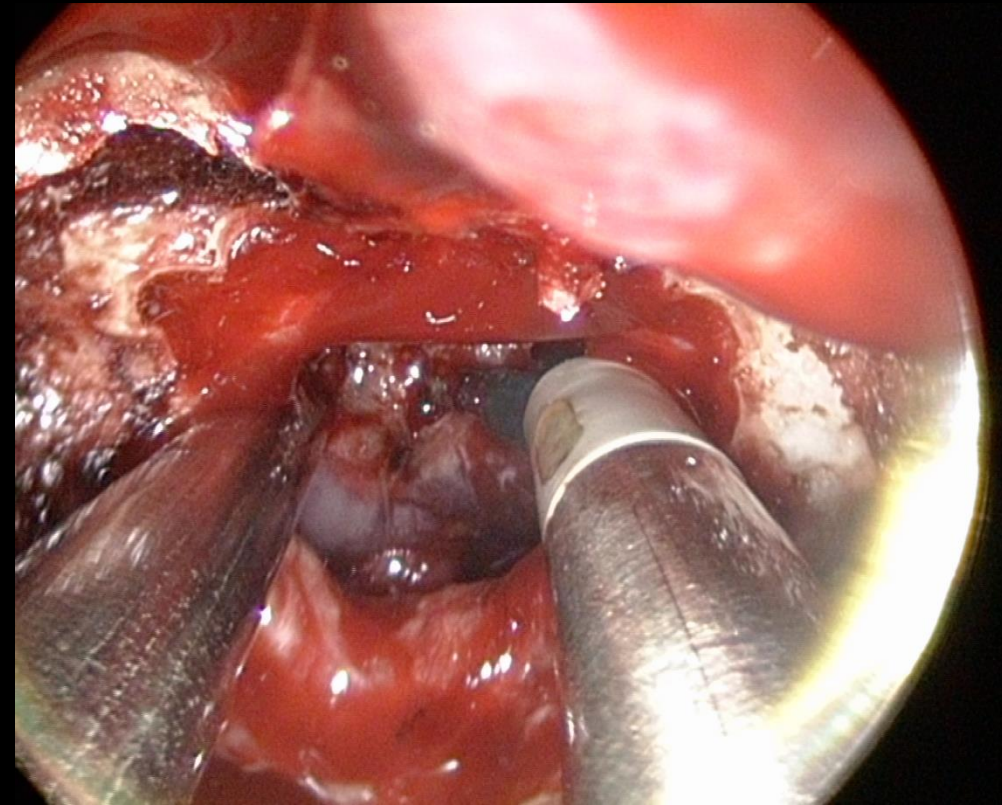
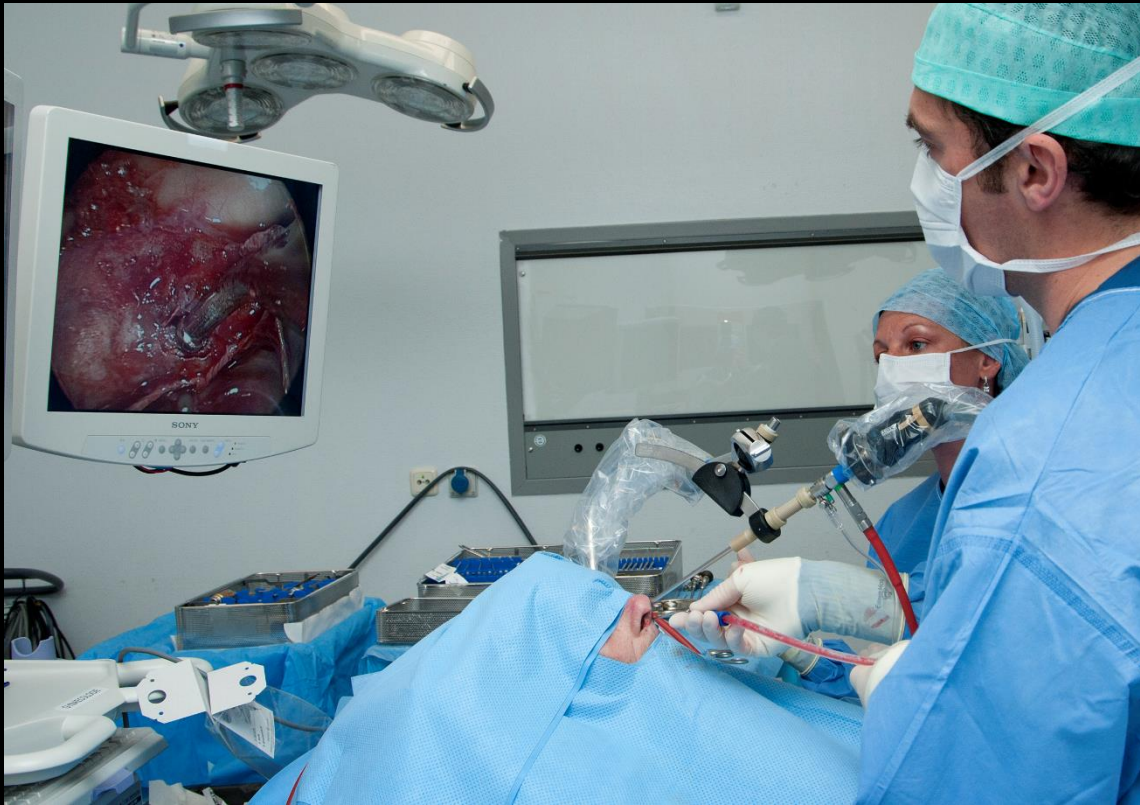Microscoop



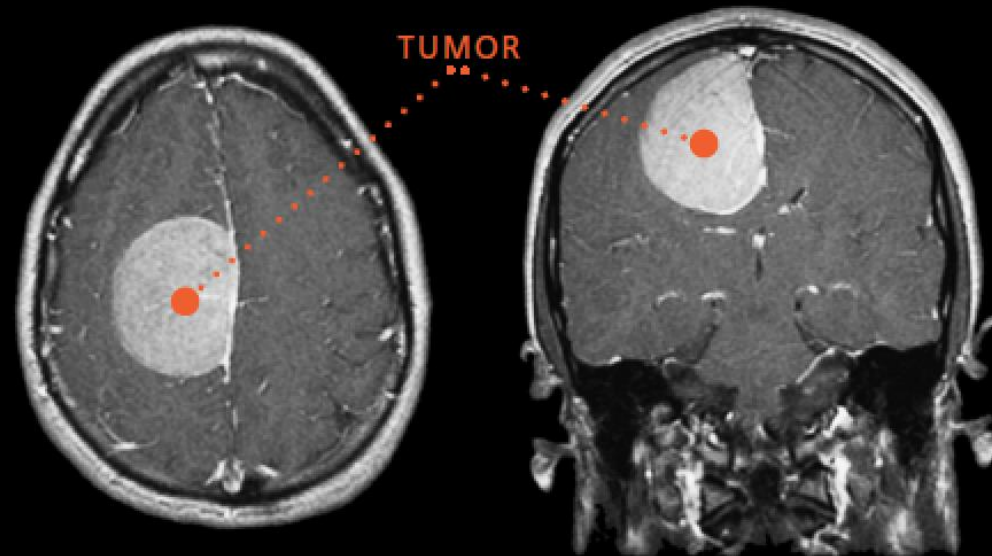
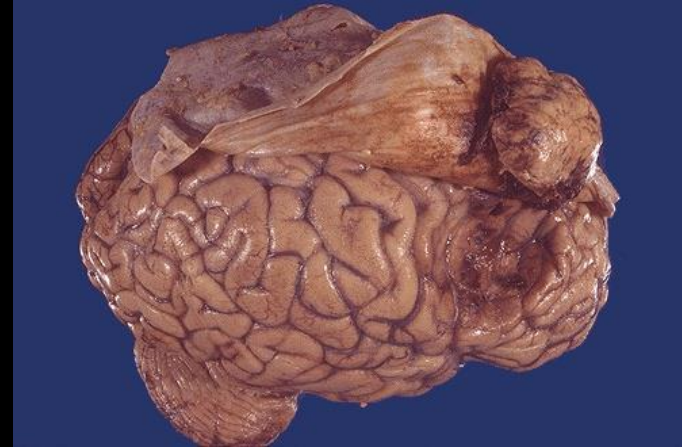
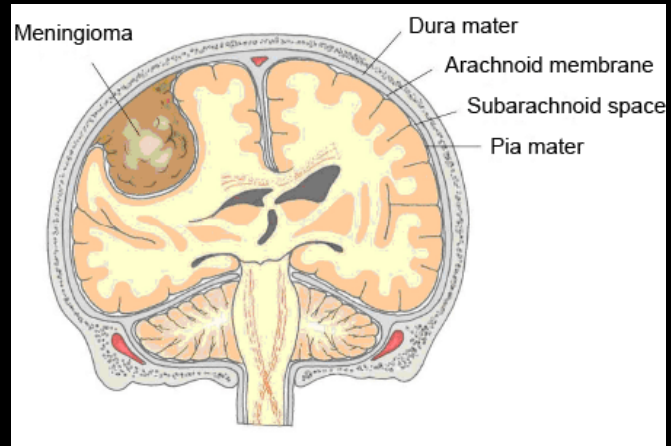
Endoscopische operatie (door de neus)



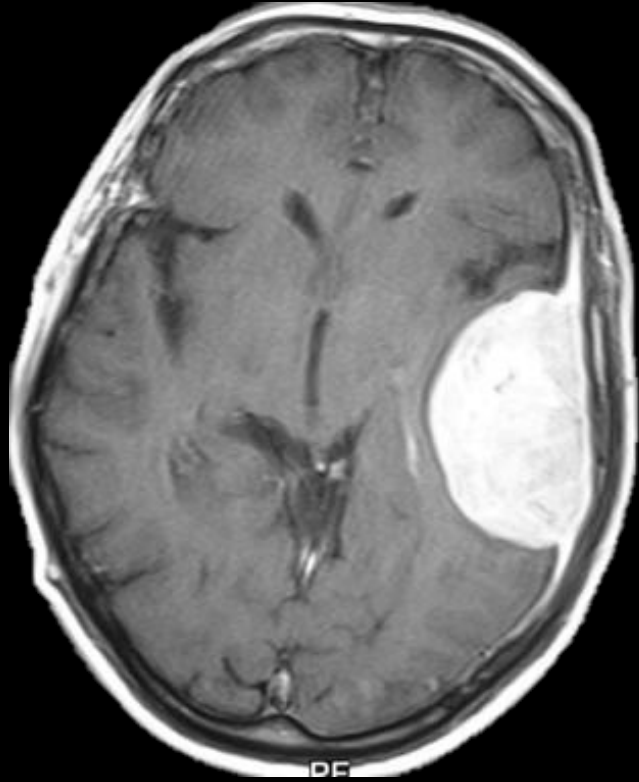
Endoscopische operatie (door de neus)



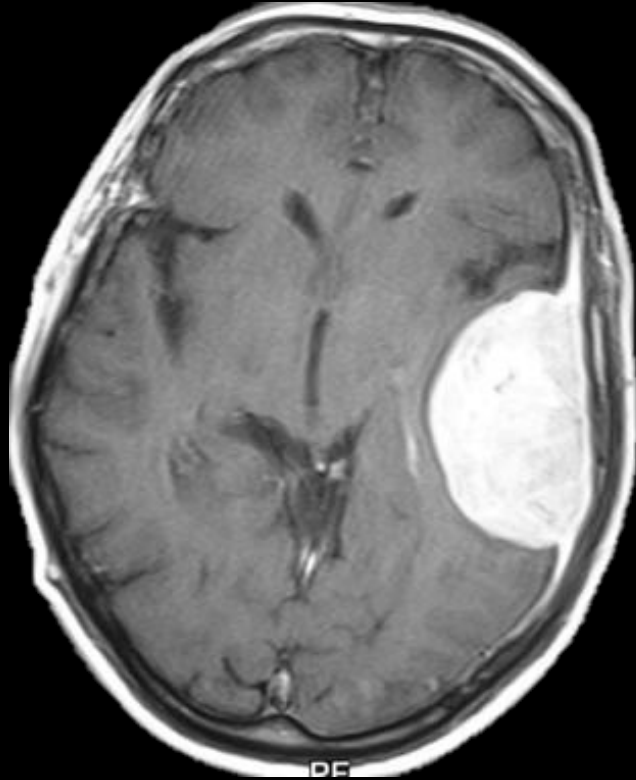
Meningioma



Een 'goedaardige' tumor

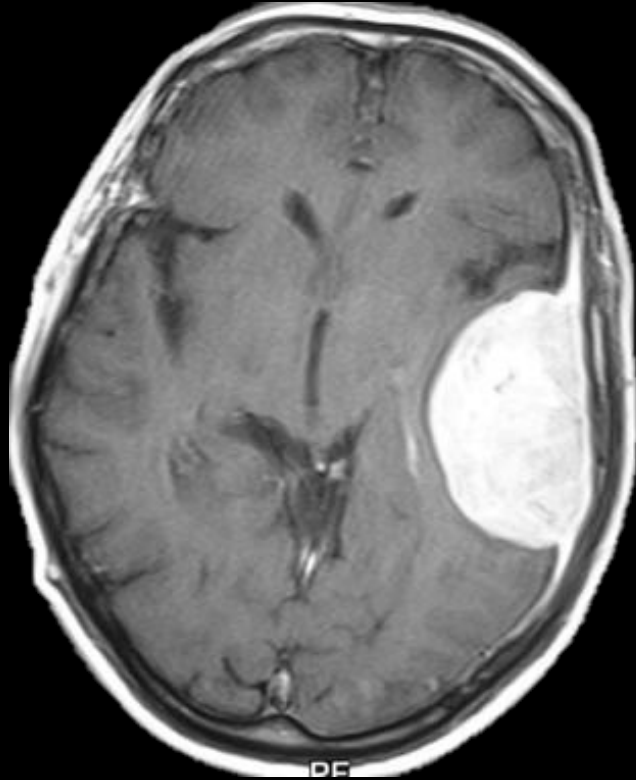


Verschillend perspectief



- geen neurologische uitval 👍
- geen pijn 👍
- tumor met relatief goede prognose 👍
- postoperatieve MRI toont geen recidief tumor 👍

Verschillend perspectief

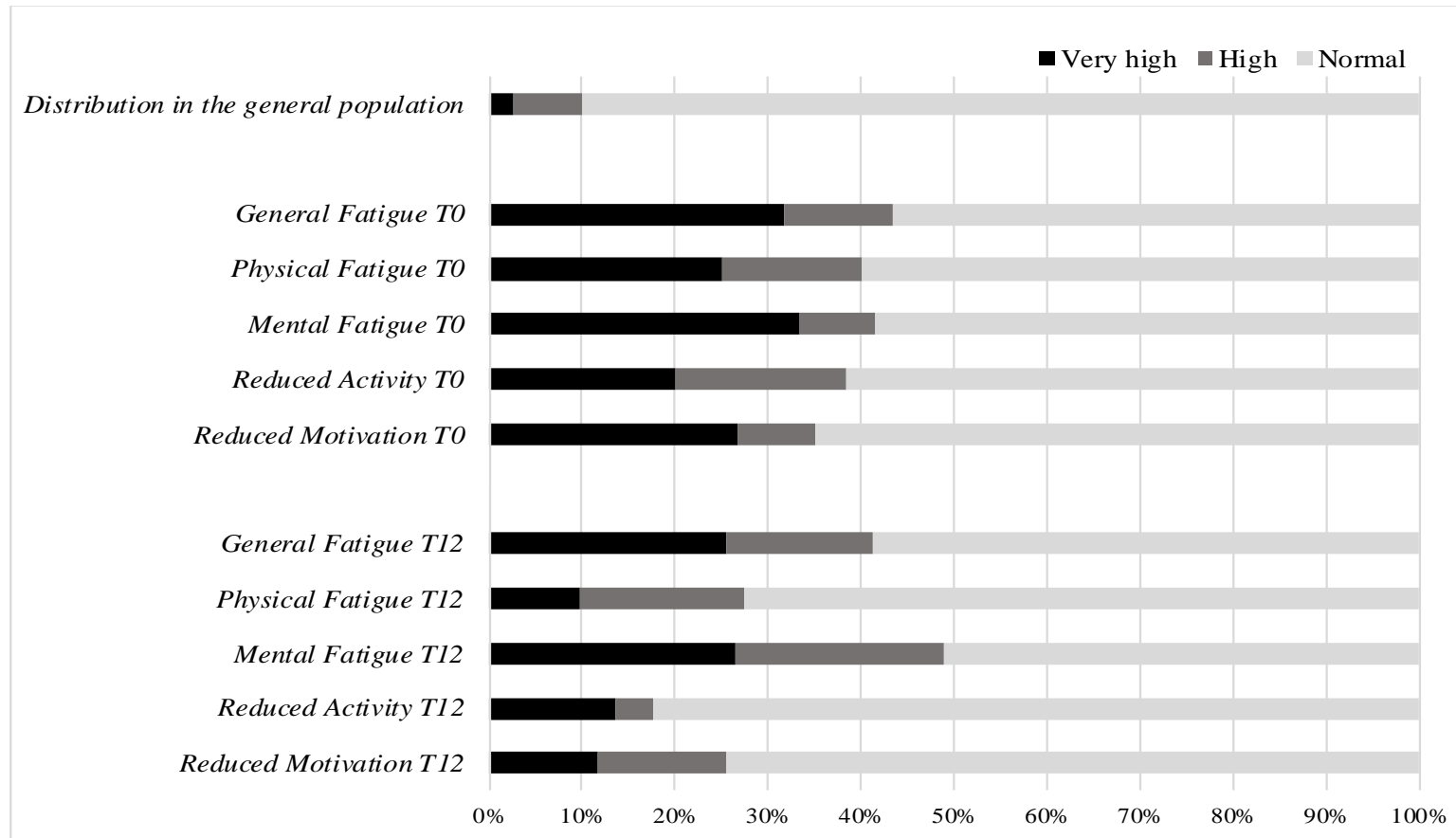


- geen neurologische uitval 👍
- geen pijn 👍
- tumor met relatief goede prognose 👍
- postoperatieve MRI toont geen recidief tumor 👍
- moeheid 🚫
- moeite met concentratie en focus 🚫
- verlies van autonomie 🚫

Vermoeidheid bij patiënten met een meningioom

vóór operatie

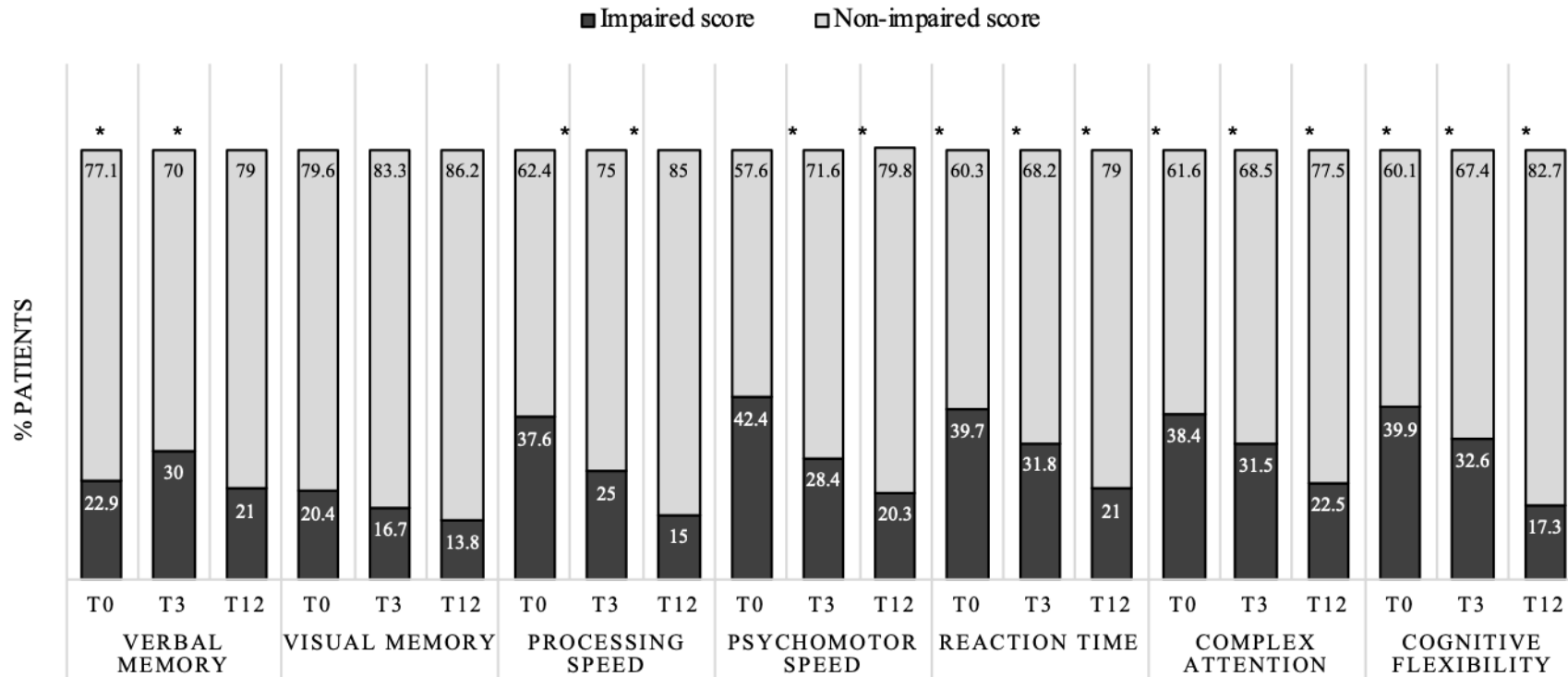
1 jaar na operatie



vd Linden et al, submitted



Denkstoornissen bij patiënten met een meningioom



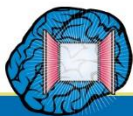
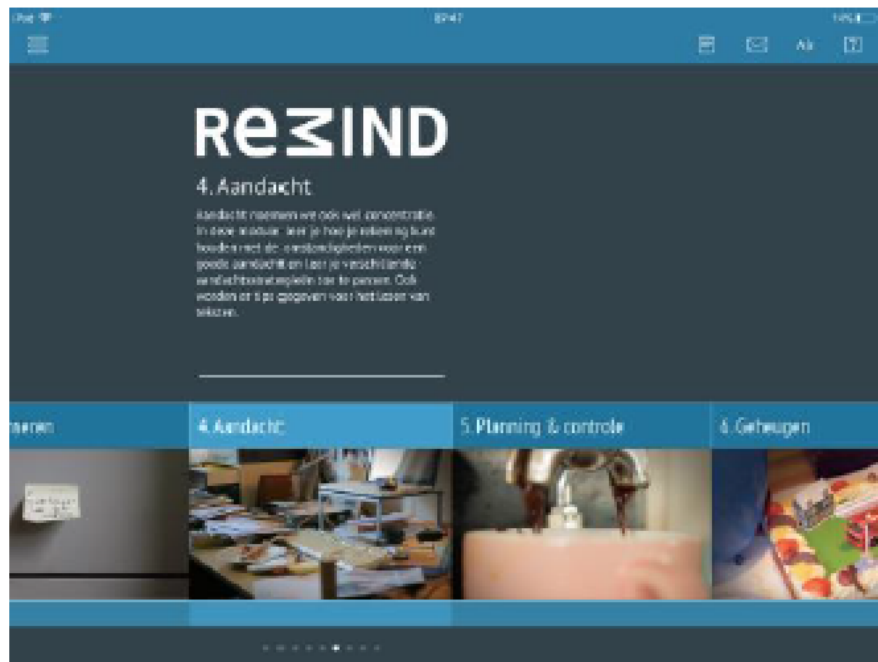
CNS VITAL SIGNS COGNITIVE DOMAINS

Rijnen et al, Neuro-Oncology 2019

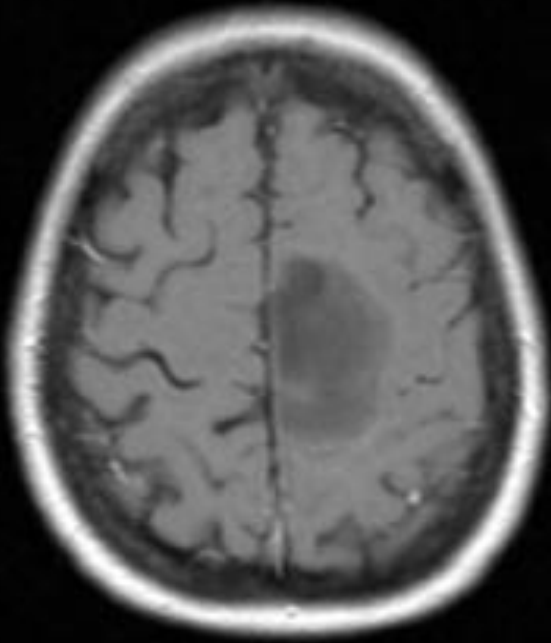


Educatie en revalidatie

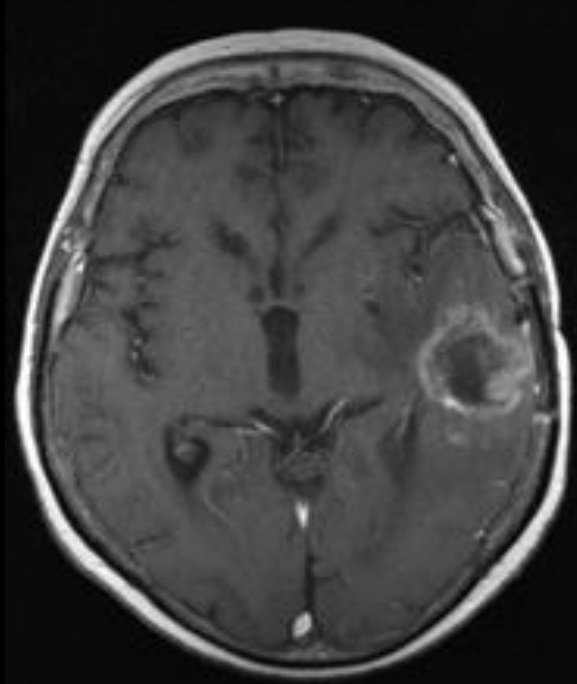
ReMIND: Een revalidatie app voor hersentumorpatiënten



Glioom




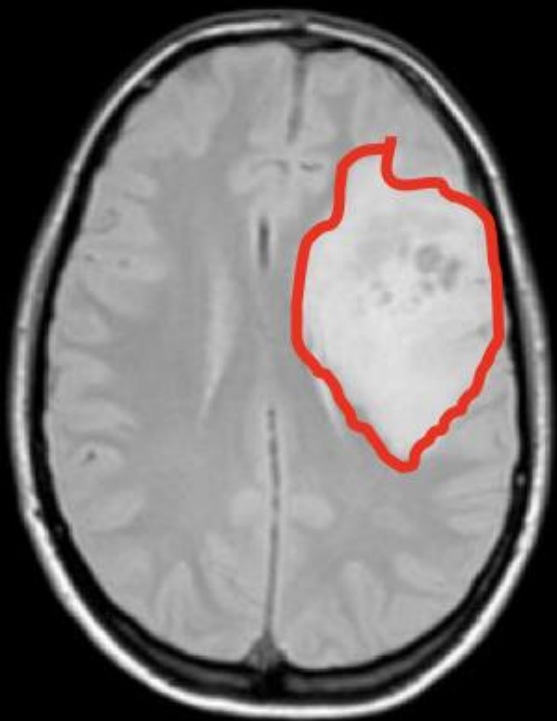
**Langzaam
groeiend**



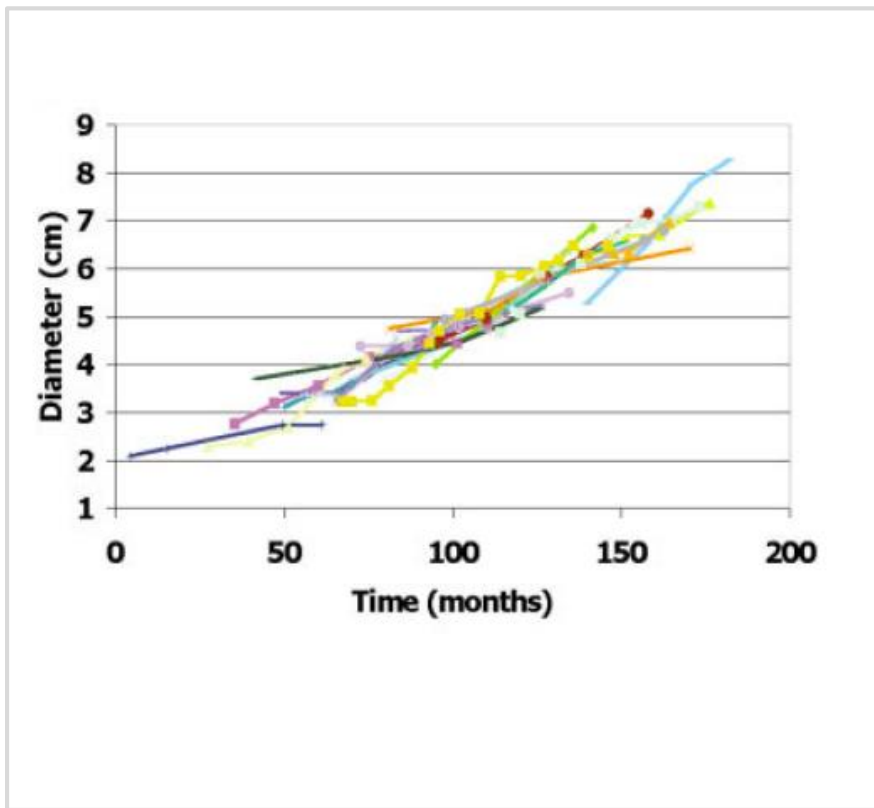
**Snel
groeiend**



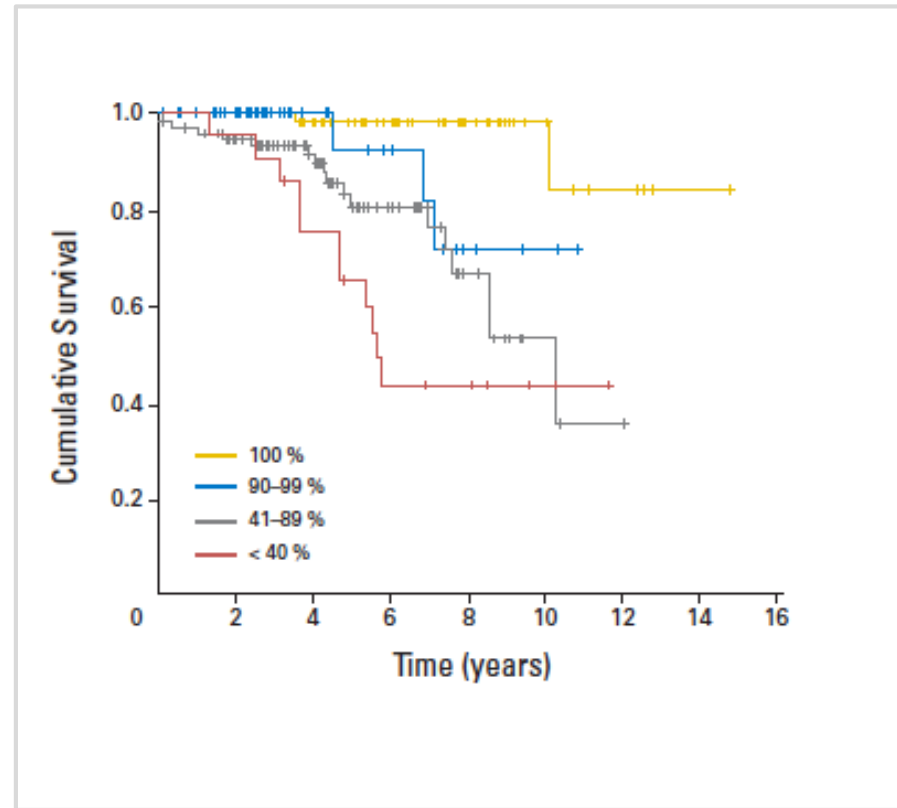
Waar is de grens?



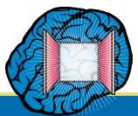
Laaggradig glioom



Mandonnet, 2003, Annals of Neurology

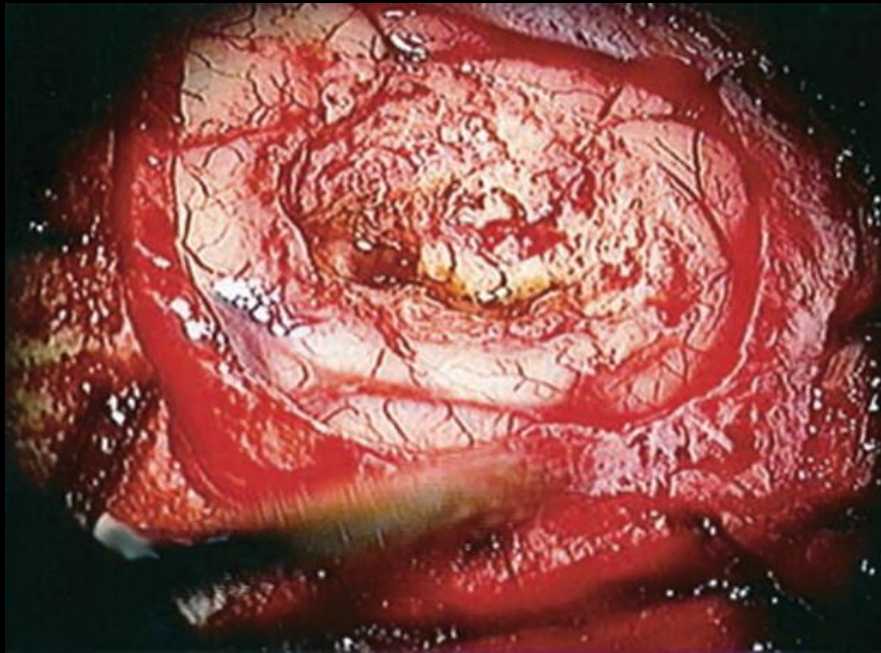


Smith, 2008, Journal of Neuro-Oncology

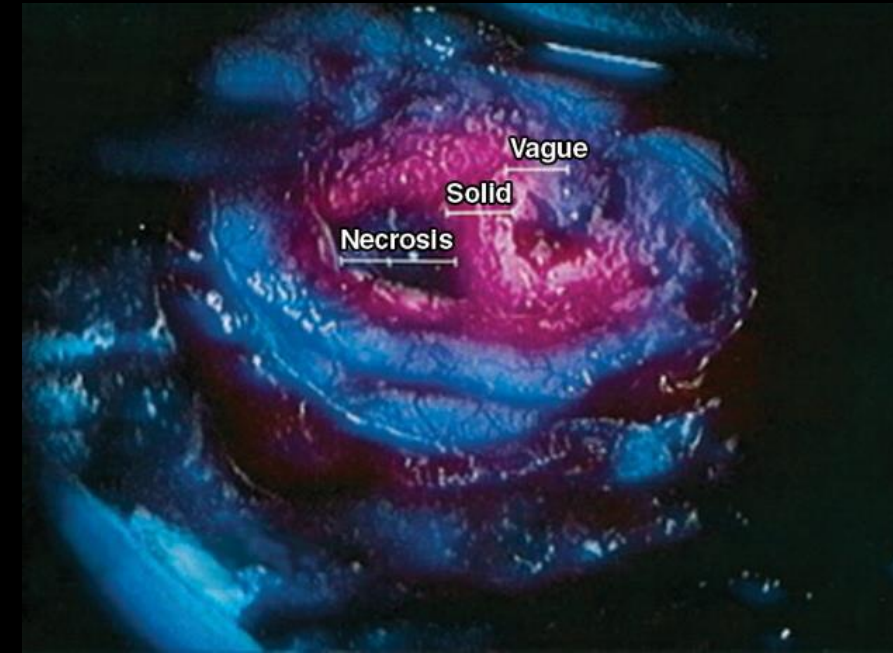


Hooggradig glioom

5-ALA / Gliolan®

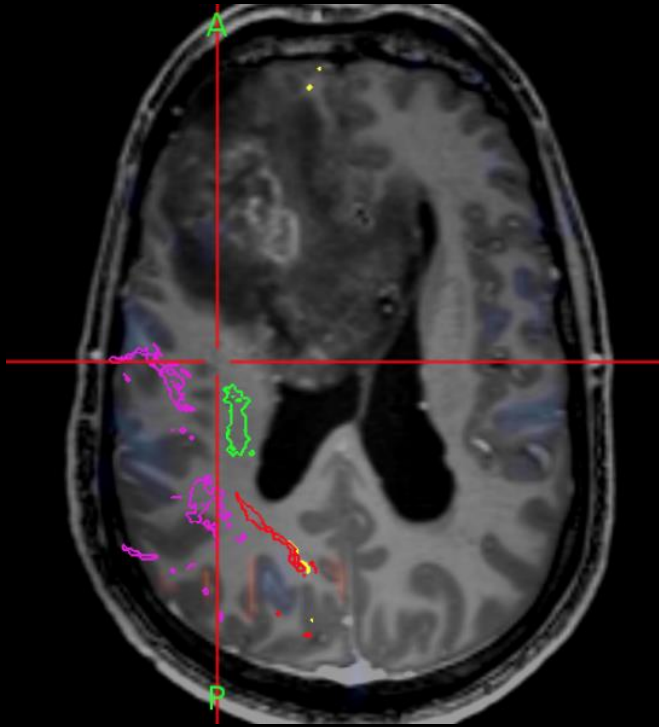


Conventioneel licht

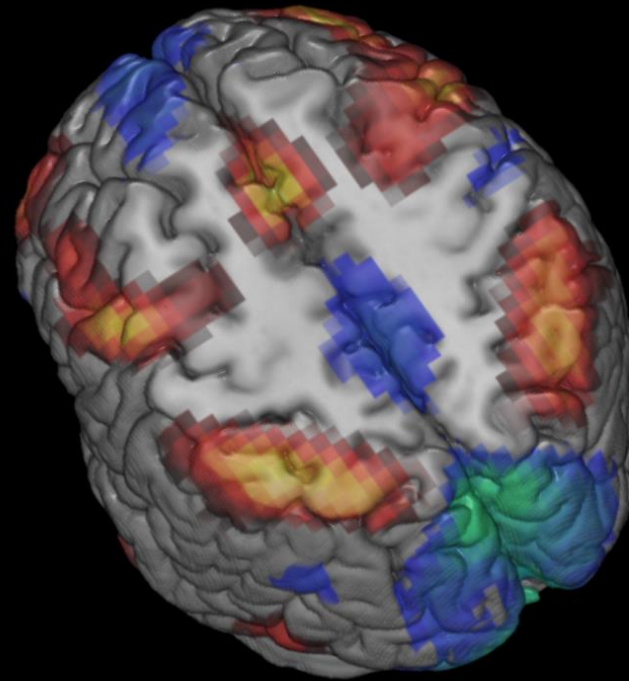


Blauw-violet licht

Opereren in de hersenen: *kritische structuren*

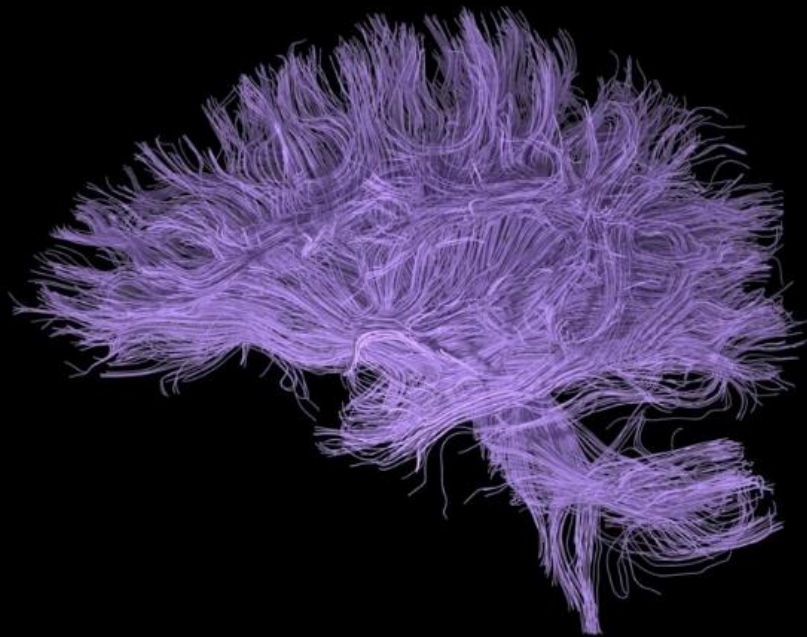


verbindingen

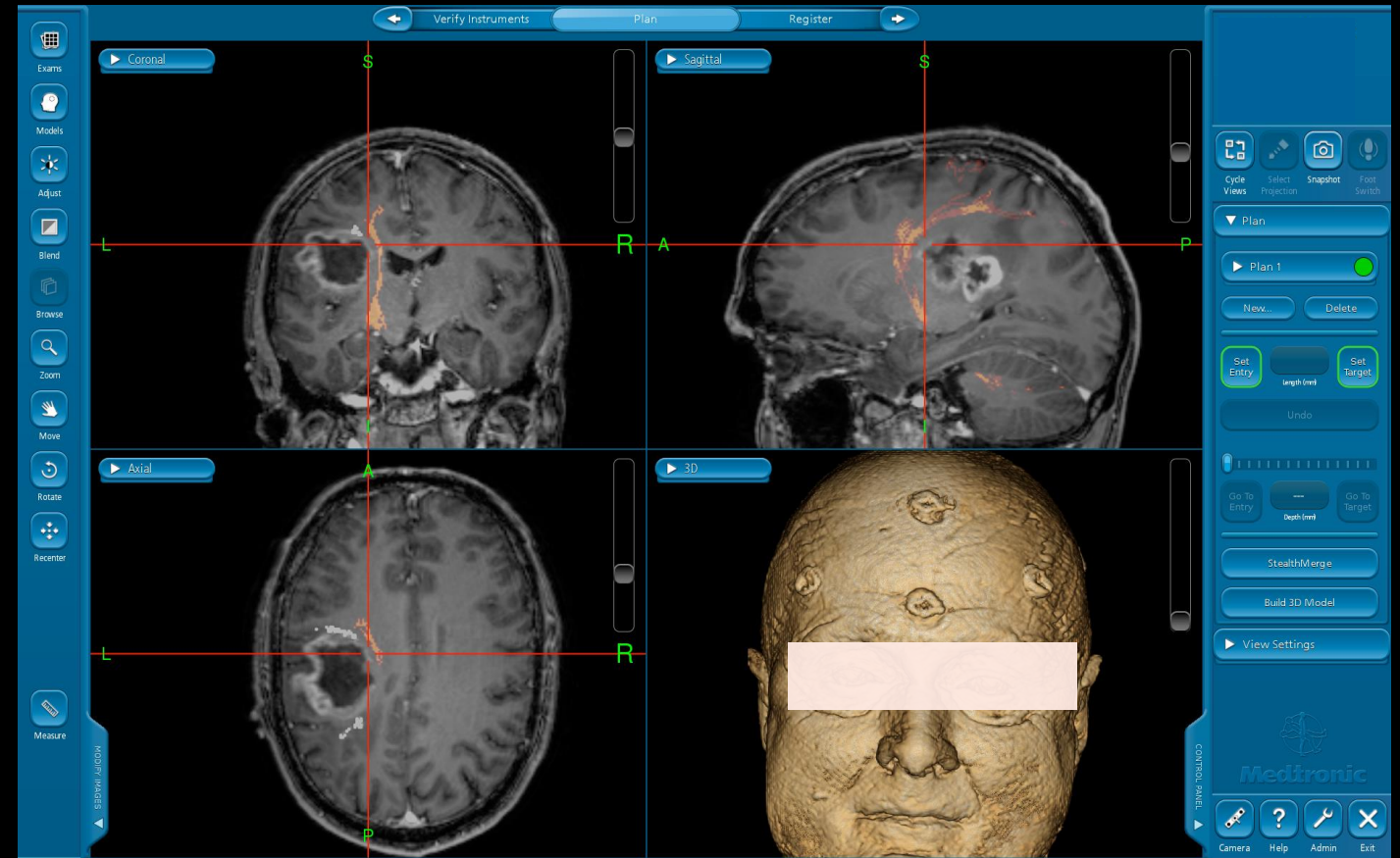


gebieden

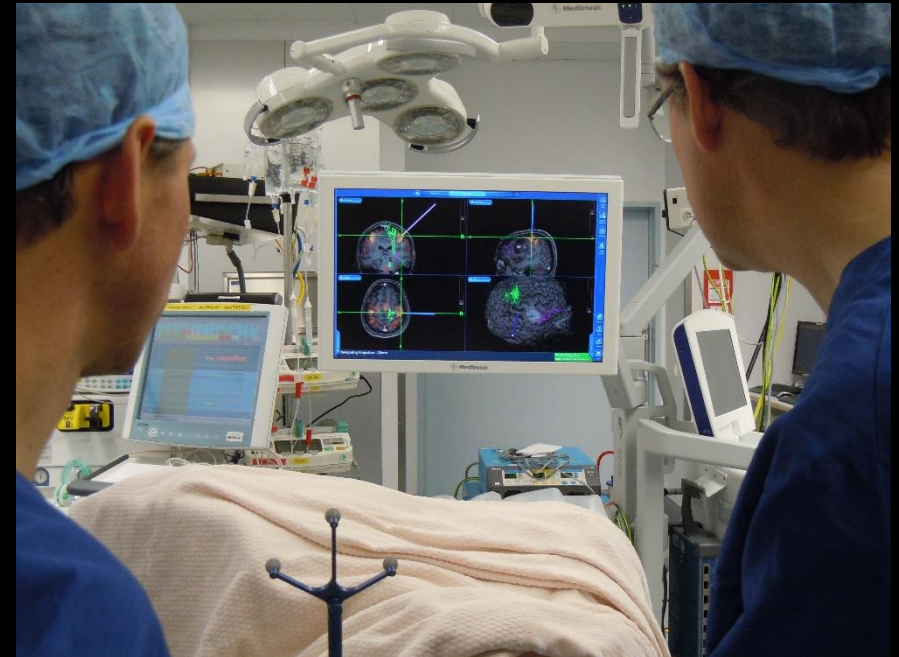
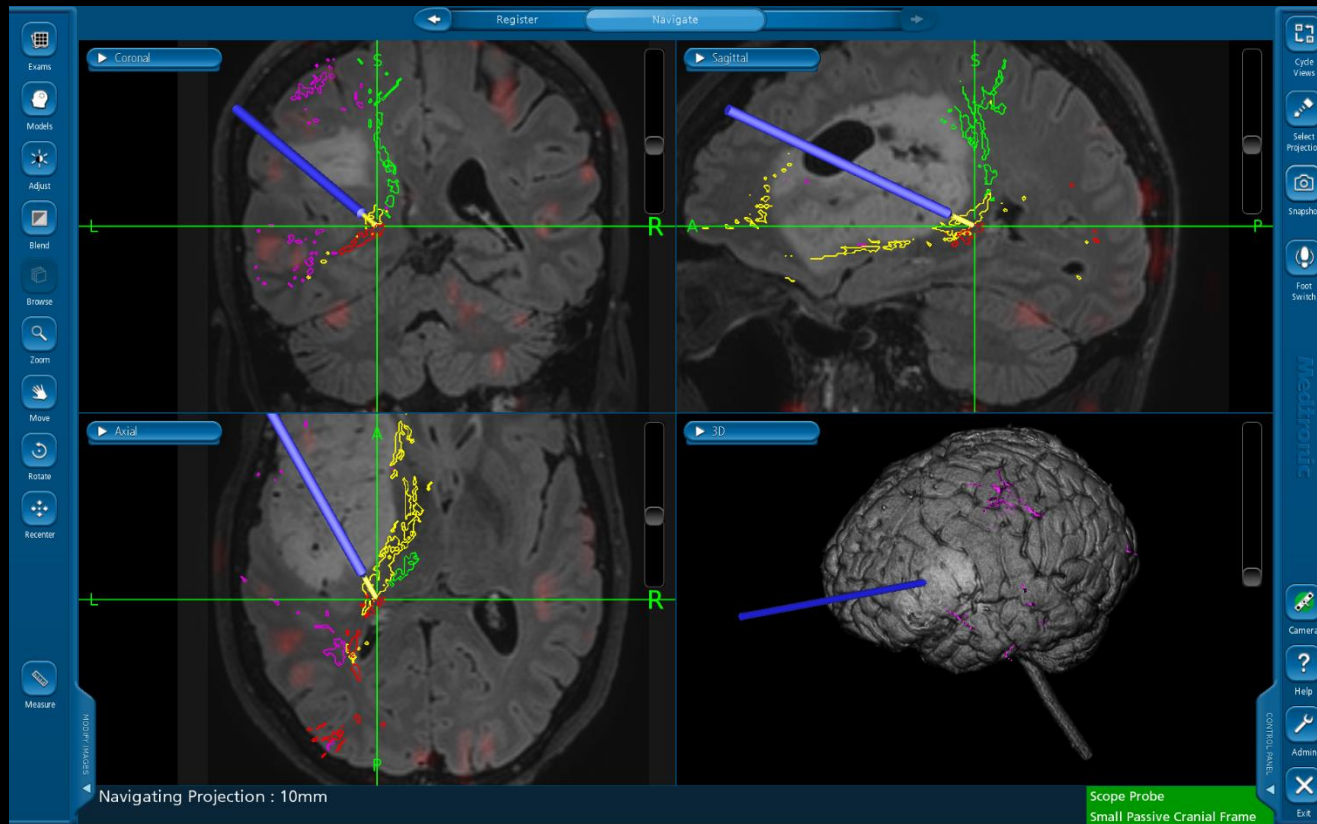
Risico inschatting voorafgaande aan operatie



'tractografie'



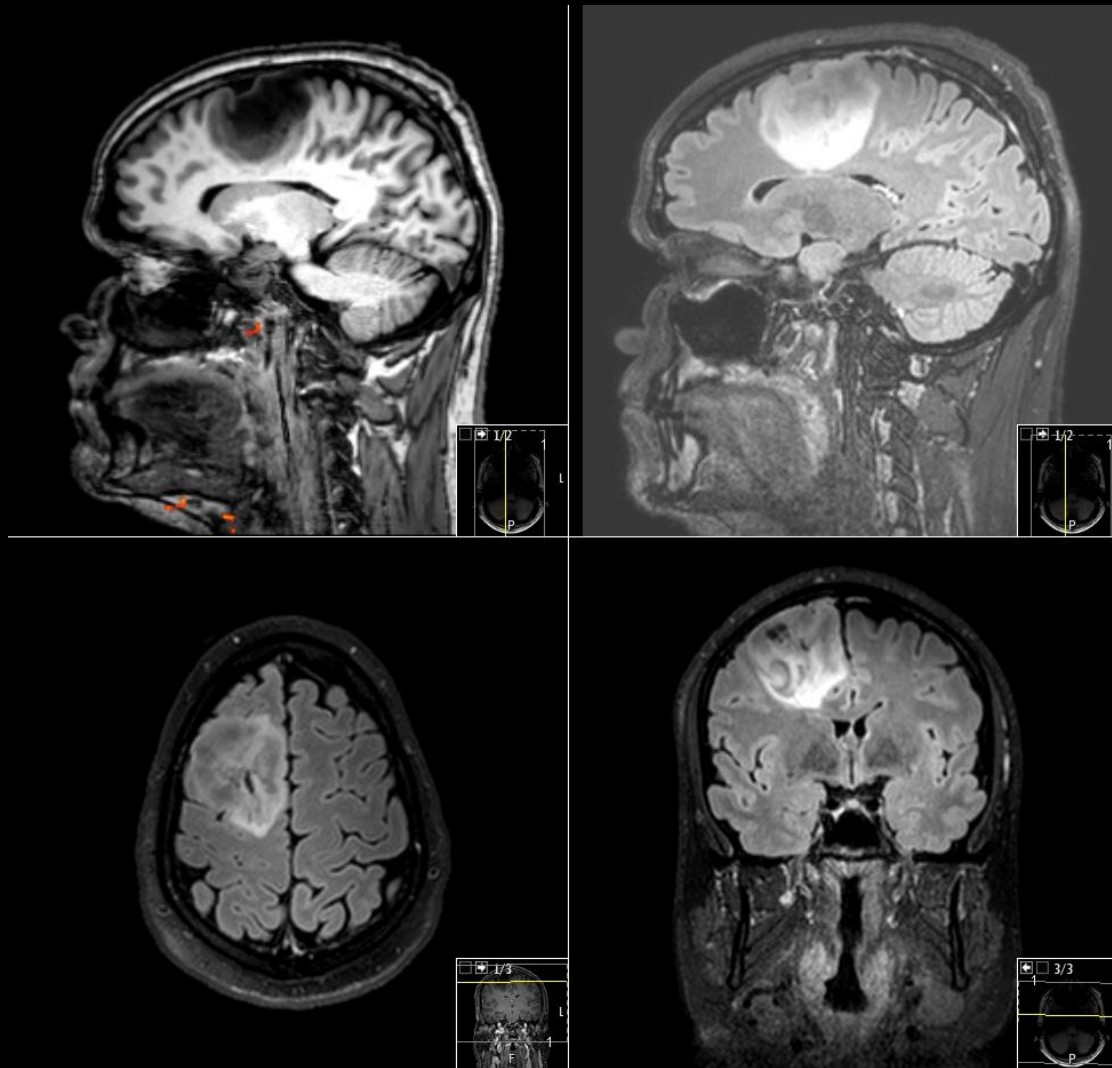
Risico inschatting voorafgaande aan operatie



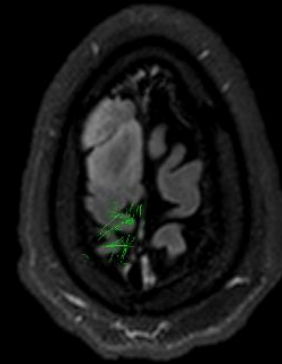
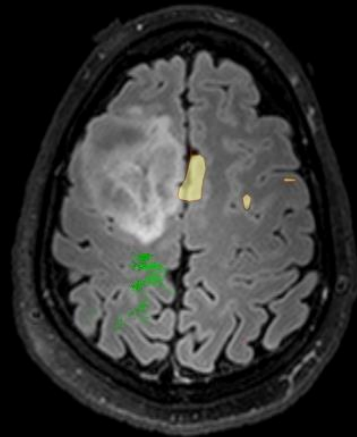
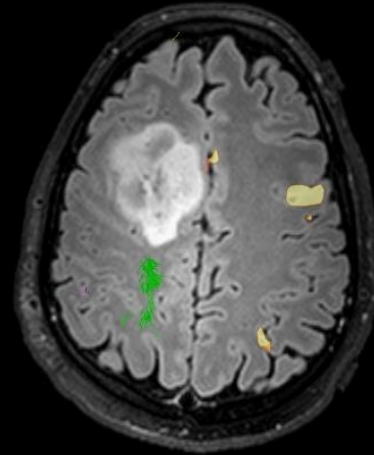
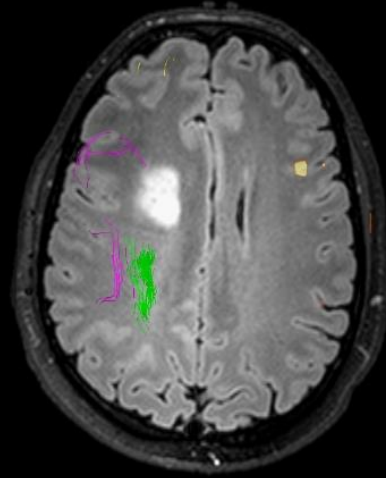
taal **motoriek** **gezichtsvermogen**

Praktisch voorbeeld

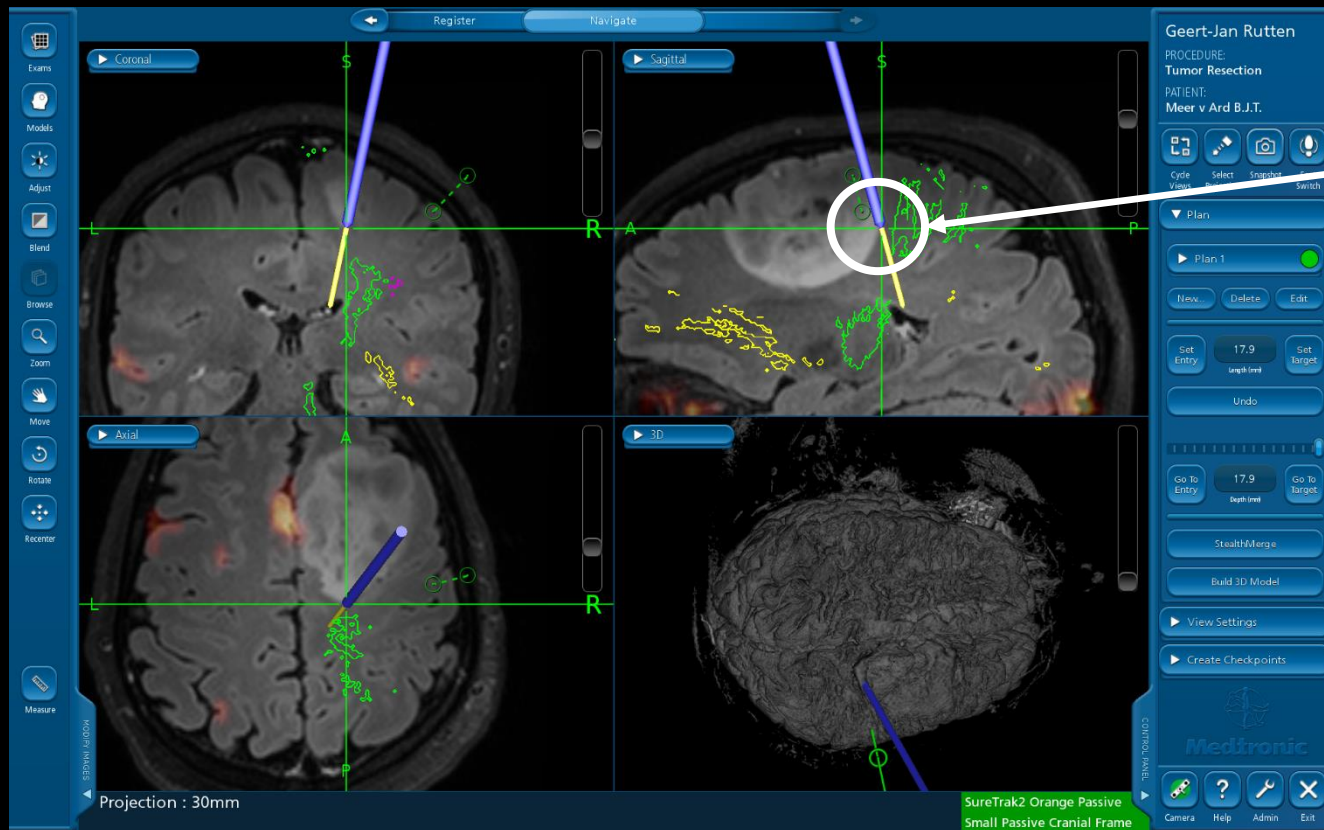
M, 38 jaar, epilepsie



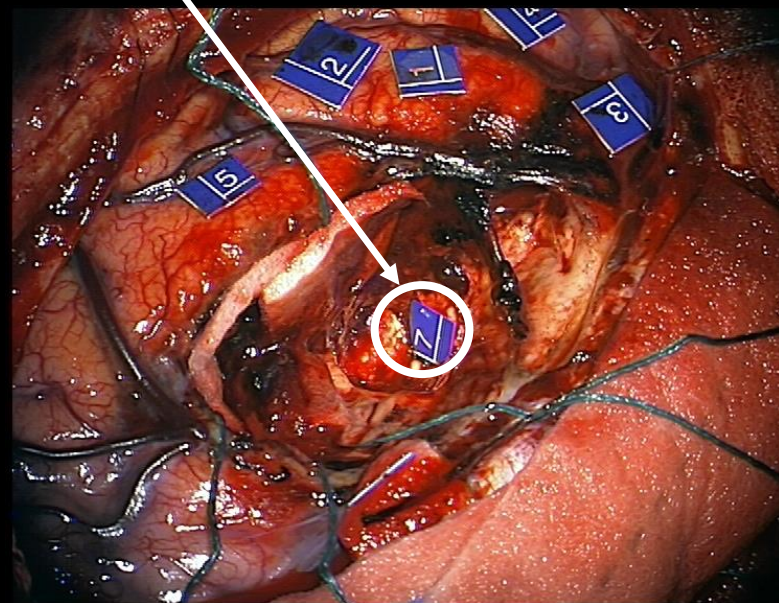
Praktisch voorbeeld



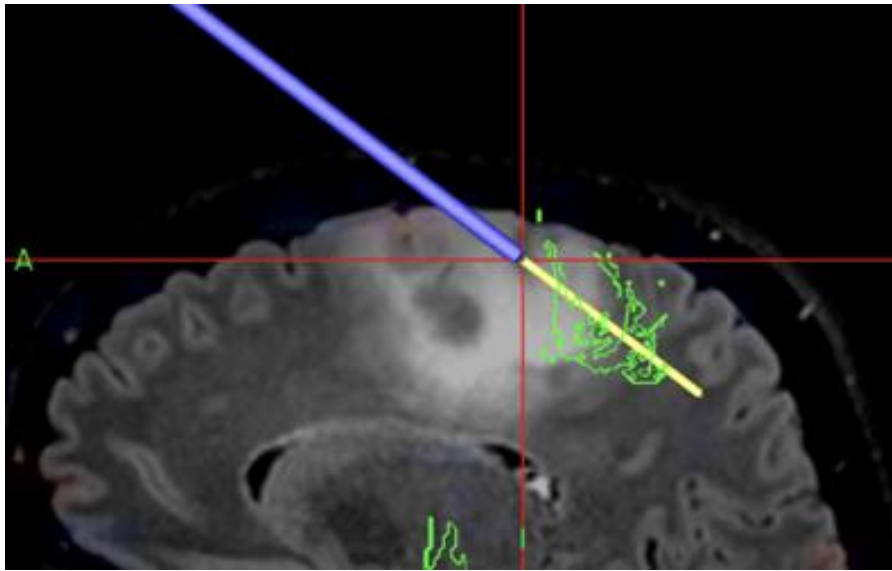
Praktisch voorbeeld



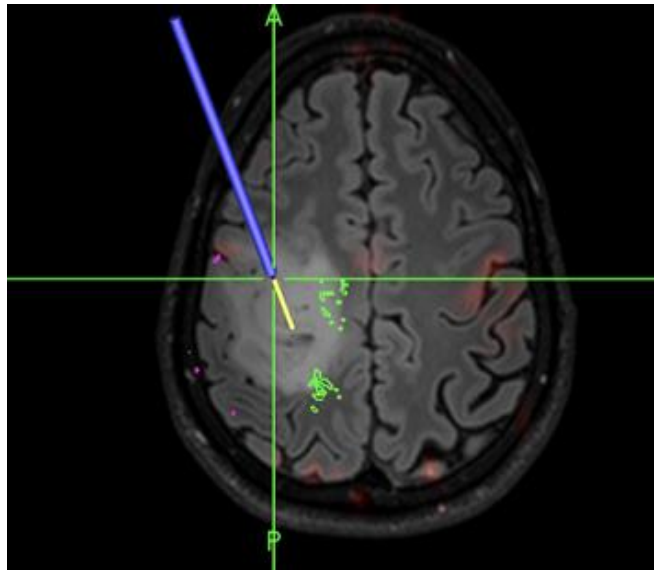
Meest kritische punt



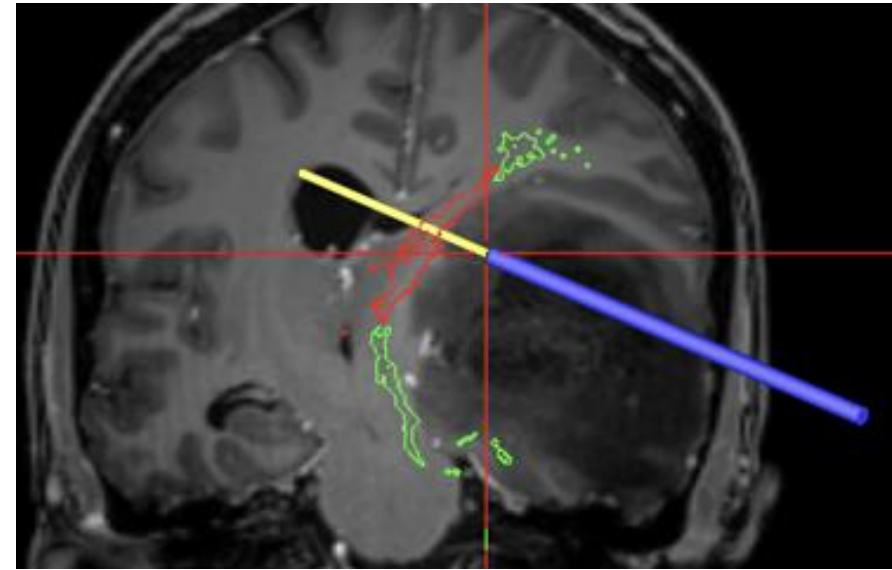
Risico inschatting voorafgaande aan operatie



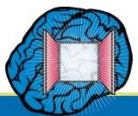
ingroei



ingroei

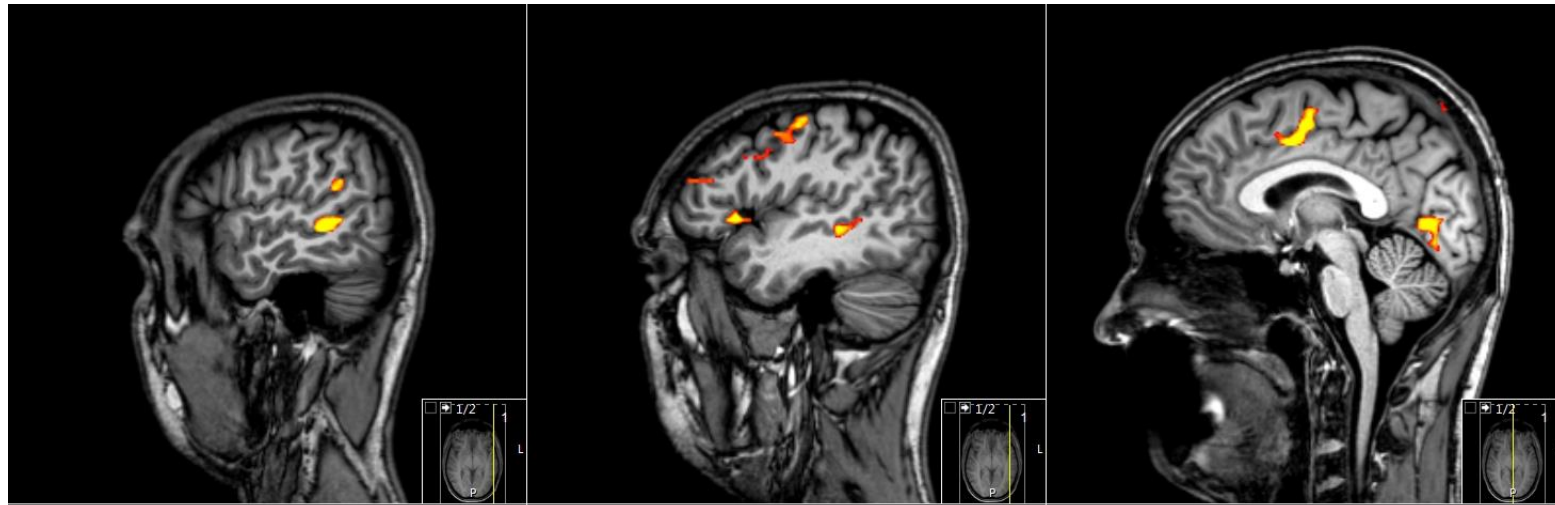


verplaatsing

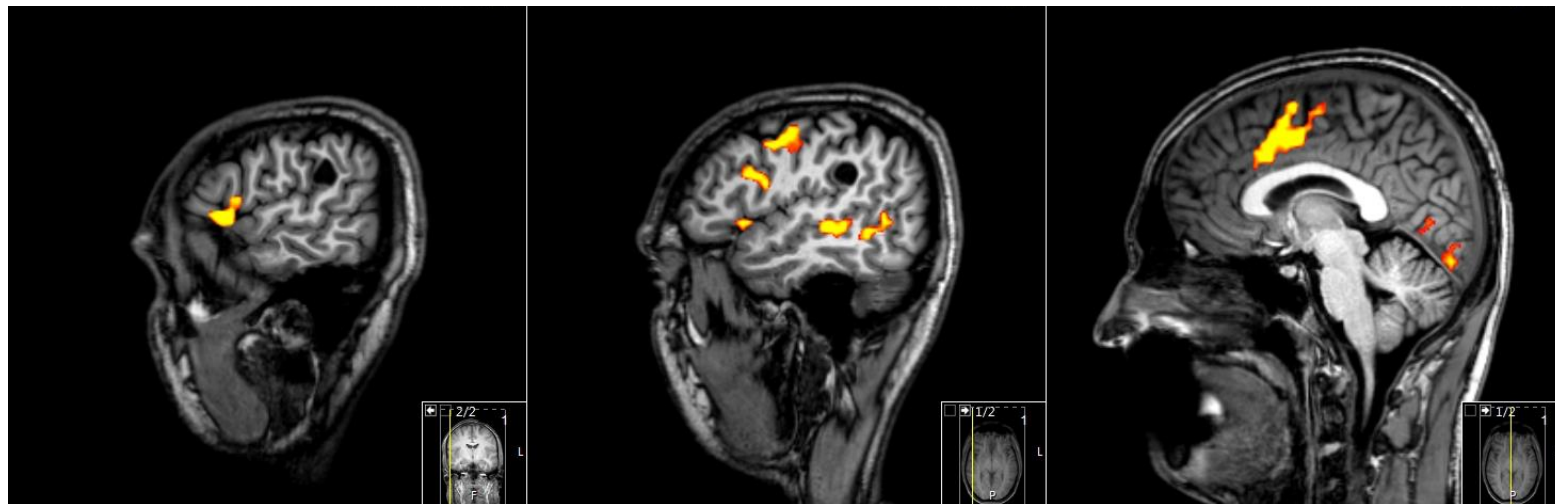


Risico inschatting voorafgaande aan operatie

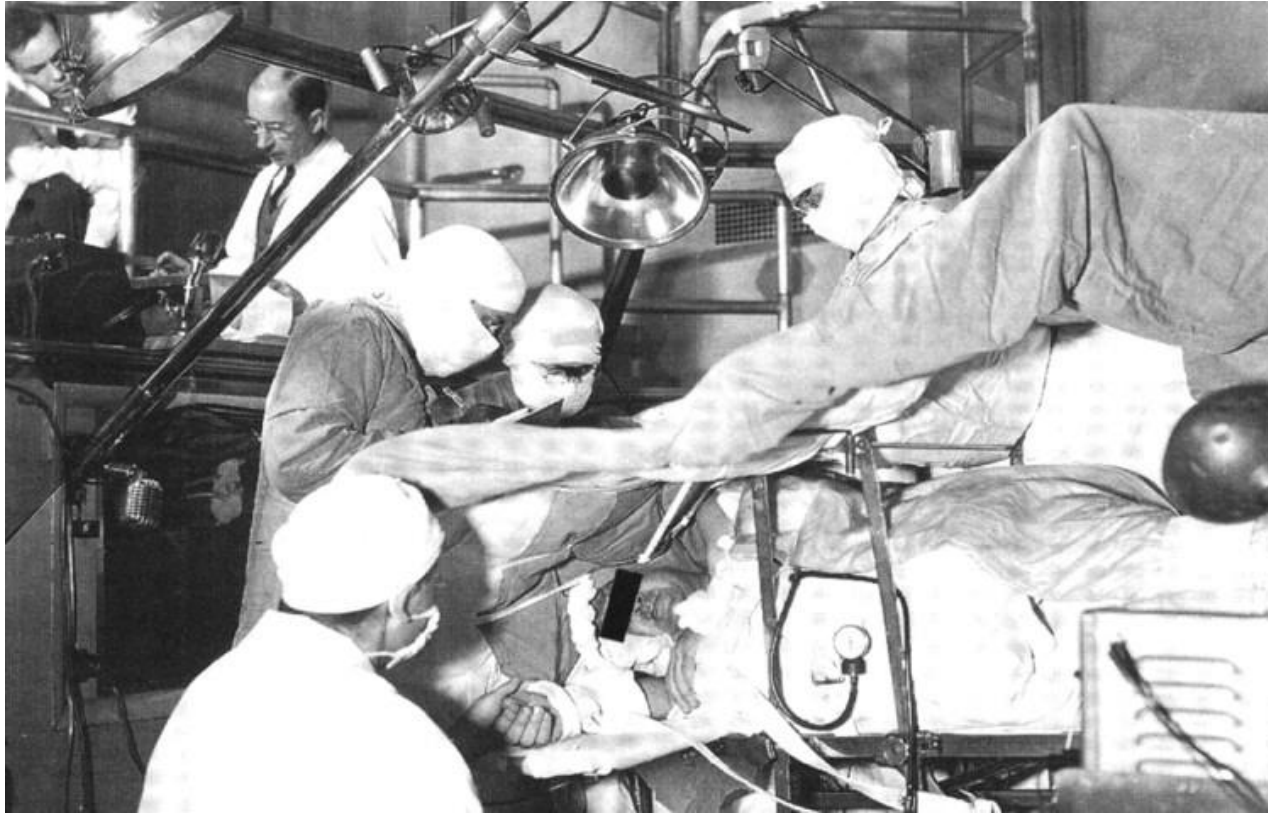
linker hersenhelft →



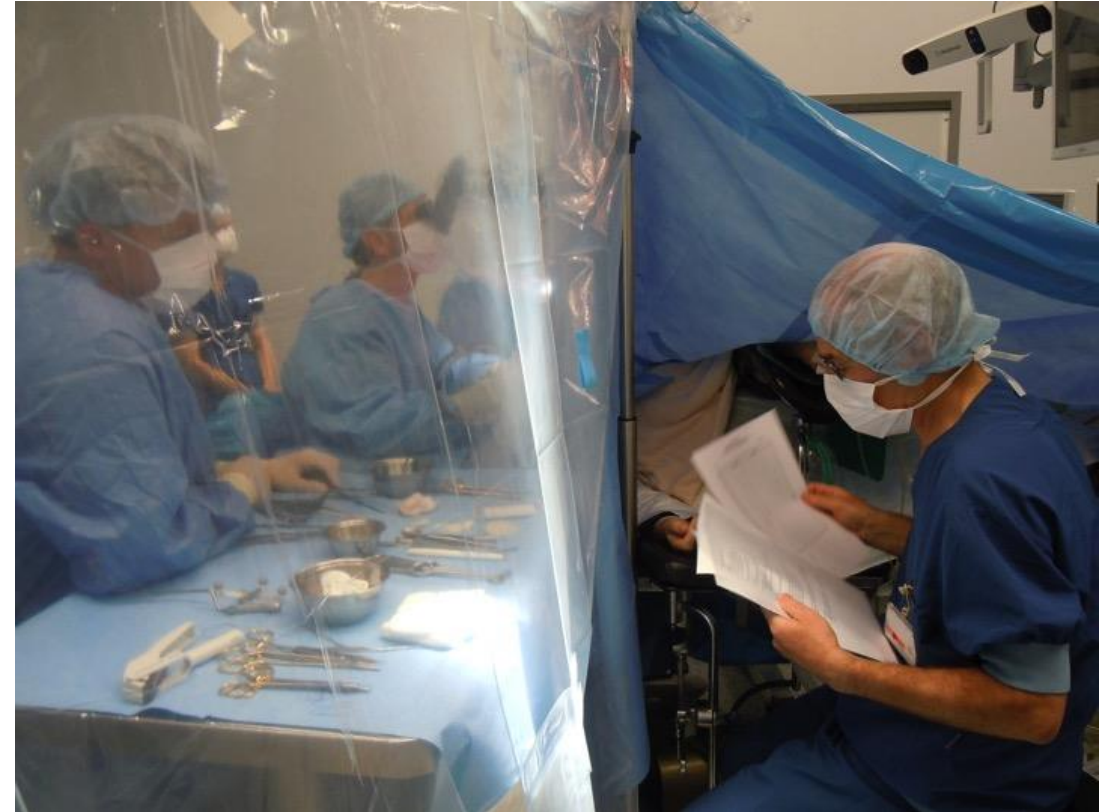rechter hersenhelft →



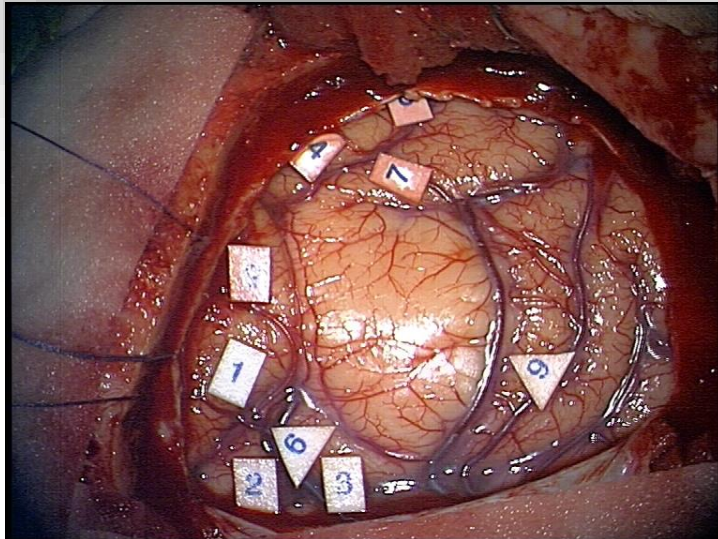
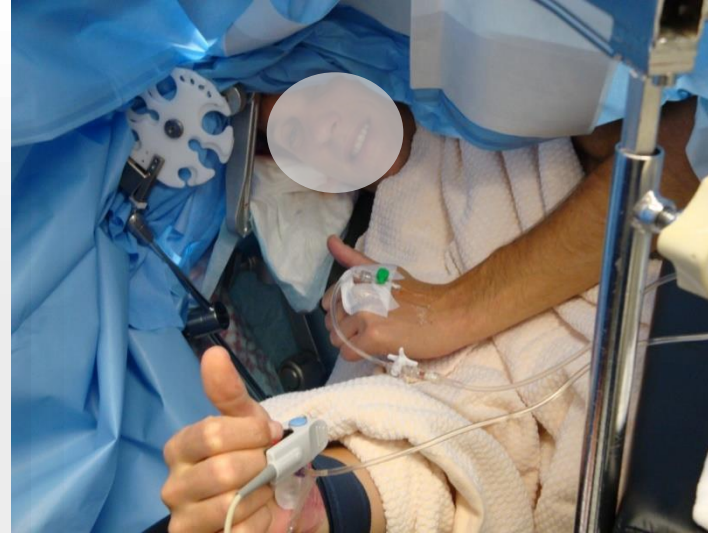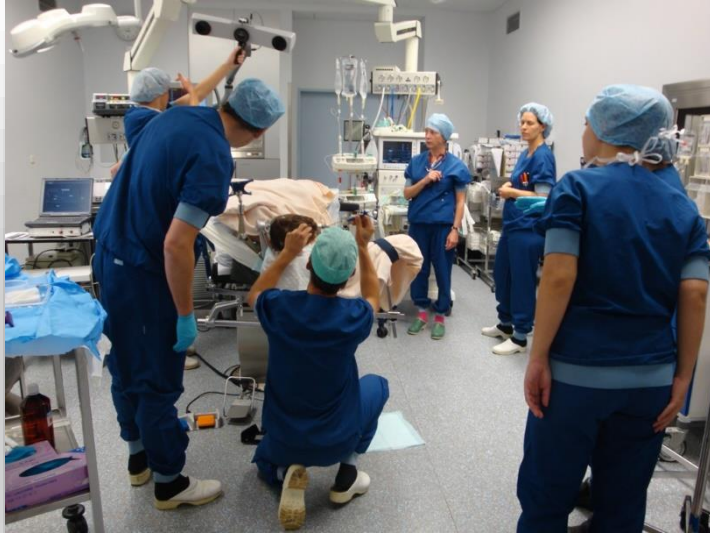Risico inschatting tijdens operatie: *'gouden standaard'*



Wilder Penfield
Montreal Neurological Institute
(ca 1958)



Risico inschatting tijdens operatie: 'gouden standaard'



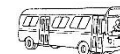Dit is een:



Dit is een:



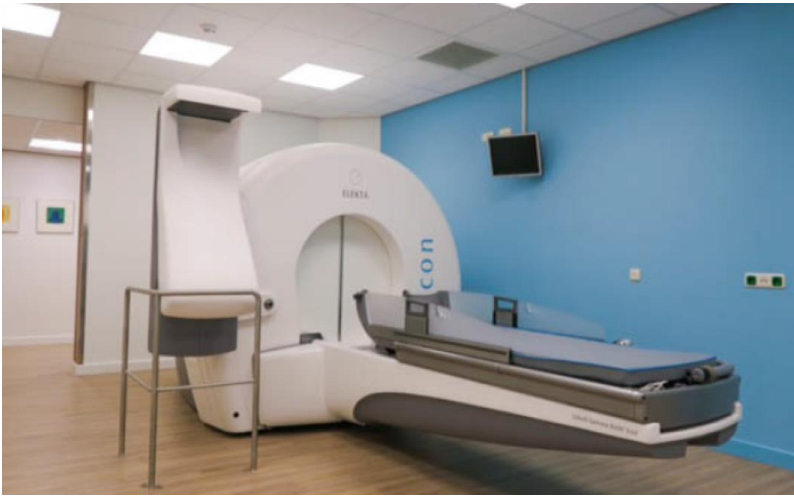Dit is een:



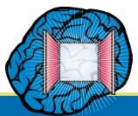
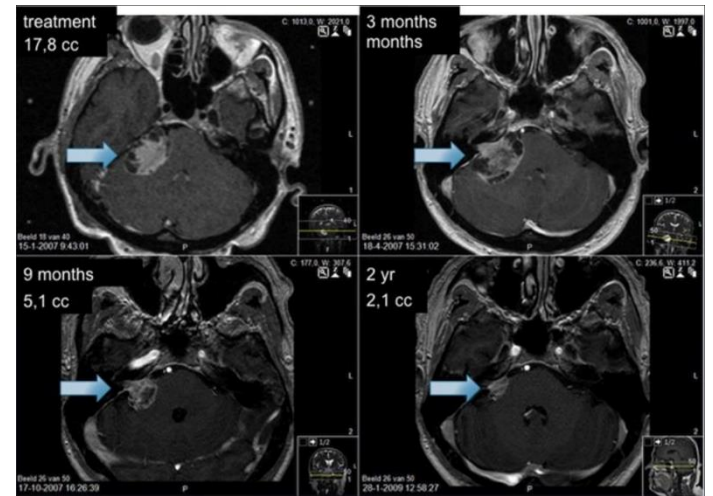
Dit is een:



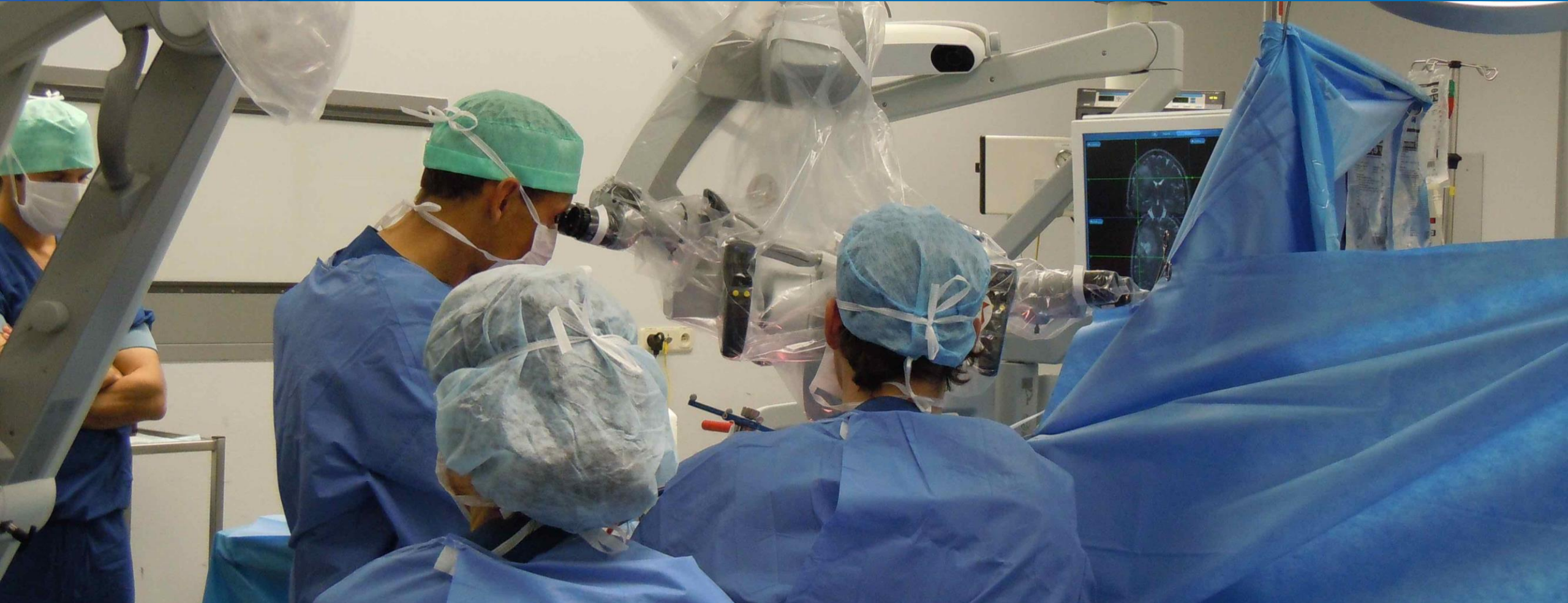Radiochirurgie is soms een alternatief voor operatie



- Meningioom
- Metastase
- Brughoektumor
- **Niet** voor glioom



Bedankt



Geert-Jan Rutten

g.rutten@etz.nl

Elisabeth-Tweesteden Ziekenhuis --- Tilburg

